

Contribution of alternative complement pathway to delayed hemolytic transfusion reaction in sickle cell disease

Transfusion of red blood cells (RBC) remains a primary treatment modality in patients with sickle cell disease (SCD). Repeated exposure to alloantigens on transfused RBCs can lead to alloantibody formation that can increase the risk of delayed hemolytic transfusion reaction (DHTR).¹ The incidence of DHTR in transfused adult SCD patients ranged from 4.8-7.7% during a 30-month and 5-year study period, respectively.^{2,3} The case fatality rate is 6%.⁴ The symptoms of DHTR typically appear 7-14 days post-transfusion and include generalized pain, hemoglobinuria with/without fever, a significant drop of total hemoglobin and hemoglobin A from the post-transfusion value and suboptimal reticulocyte response. These clinical features mimic a classic vaso-occlusive pain crisis (VOC), further confounding the detection of DHTR. In addition, patients can experience hyperhemolysis, evidenced by hemolysis of both native and transfused RBCs. General management of DHTR depends on the extent of hemolysis and the patient's clinical condition, from supportive care strategies to high dose erythropoietin, intravenous immunoglobulin (IVIg), and immunosuppression.^{4,5}

We report here comprehensive data on a 14-year-old African American female with SCD ($\beta^0\beta^0$ genotype) and evidence for alternative complement pathway (ACP) activation during two of her three DHTR hyperhemolysis episodes, one of which had no new detectable allo- or autoantibody. This patient's past medical history is significant for multiple episodes of acute chest syndrome (ACS) and VOC, and an episode of acute splenic seques-

tration. The first episode of DHTR occurred at seven years of age, about nine days after receiving an extended phenotype-matched and crossmatch-compatible RBC transfusion for VOC and ACS (Figure 1A). A new anti-S antibody and anti-Dia antibody were detected in the serum, with a negative direct antiglobulin test (DAT). She was treated with corticosteroids and made a complete recovery.

The patient's second episode of DHTR was at 13.5 years-of-age. She was initially transfused with extended phenotype-matched and crossmatch-compatible RBCs for VOC and hemoglobin (HGB) of 4.4 g/dL (Figure 1B; day -9). Nine days after this transfusion, she presented with generalized pain and HGB of 7.2 g/dL. Within 24 hours of presentation, she progressed to having fevers, profound hemolysis (HGB 3.1 g/dL), thrombocytopenia ($120 \times 10^3/\mu\text{L}$), and absolute reticulocytopenia 75% below her baseline. Also, there was evidence for marked hemoglobinuria, liver dysfunction and acute kidney injury (creatinine 0.9 mg/dL; baseline 0.5 mg/dL). Immunohematology testing revealed a new anti-Sda antibody, a cold agglutinin in the serum, and a negative DAT. Mycoplasma IgM in serum was positive, suggestive of acute mycoplasma infection. The patient responded well to 150 IU/kg of erythropoietin, corticosteroids and additional extended phenotype-matched and crossmatch-compatible RBC transfusions on days 2 and 4 to mitigate the ongoing effects of hemolysis from antibody-mediated DHTR and cold agglutinin syndrome (CAS). Hyperhemolysis and multi-organ involvement prompted analysis of complement proteins, which subsequently revealed elevated anaphylatoxin, C5a and terminal complex, C5b-9; both support the evidence for complement activation (Table 1 DHTR#2). Complement acti-

Table 1. Evaluation of complement pathway during DHTR episodes.

	DHTR #2 (Day 6)	DHTR #3 (Day 13) Pre 1 st dose	DHTR #3 (Day 38) Pre 2 nd dose	(Day 127) Clinic visit
C3a (25-88.2 ng/ml)	43.6	75.6	79.4	27.9
C5a (2.74-16.33 ng/ml)	26.8	25.1	23.2	17.3
Bb (0.49-1.42 mcg/mL)*	0.95	6.06*	1.53	0.96
sC5b-9 (≤ 244 ng/mL)	319	270	219	81
CH50 (101-300 units)	ND	335	320	352
C3 (71-150 mg/dL)	ND	135	ND	ND
C4 (15.7-47 mg/dL)	ND	21.4	ND	ND

C3a: complement component fragment 3a; C5a: complement component fragment 5a; Bb: complement component fragment Bb; sC5b-9: soluble membrane attack complex; CH50: screening test for total complement activity; C3: complement component 3; C4: complement component 4. ND: not done. All testing was obtained in a CLIA certified hospital-based clinical laboratory. All normal values are in parenthesis under each value except for day 13 *(1.32-4.18 mcg/mL) due to variability seen with different ELISA kits. DHTR#2 signifies the second DHTR episode at 13.5 years of age with complement evaluation on day 6 of presentation. The complement testing under DHTR#3 reflects the ACP pathway testing on the days just prior to administration of eculizumab on days 14 and 39. Testing at Day 127 reflects baseline complement levels during a routine sickle cell clinic appointment when the patient was well. Fragment Bb is a serine protease that in combination with hydrolyzed complement factor 3 (C3H₂O) generates the formation of C3bBb (C3 convertase), which amplifies the cleavage of C3 to produce C3a and C3b which results in local inflammation and RBC opsonization, respectively.¹⁶ Anaphylatoxins, C3a and C5a are involved in local inflammation and tissue damage. Terminal complex, C5b-9 contributes to intravascular hemolysis.

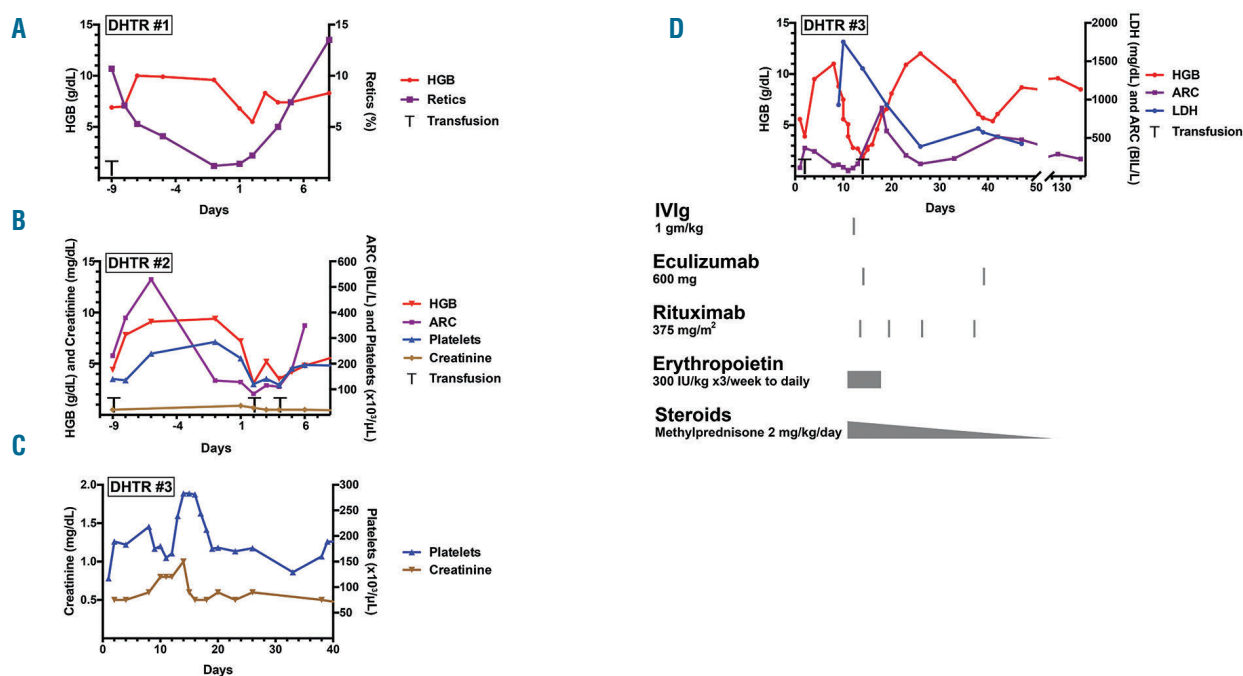


Figure 1. A graphic representation of three DHTR episodes. (A) DHTR episode #1. The patient received transfusion (T) on day -9 and presented with DHTR on day 1. (B) DHTR episode #2. Hemolysis and absolute reticulocytopenia occurred nine days after transfusion (T). (C) DHTR episode #3. Grey colored bars depict the time points when various treatments were administered. (D) DHTR episode #3 showing the doubling of creatinine to 1.0 mg/dL from baseline. Methylprednisolone at a dose of 50mg once daily was given initially on days 11 through day 18. Prednisolone weaning regimen was then started at 2 mg/kg/day on day 18 and completed on day 60. Erythropoietin was administered at the same dose of 300 IU/kg three times a week on days 11 through 14, and then given daily until day 18. Immunohematology work-up during three DHTR episodes: DHTR #1- DAT negative, anti-S (new) and anti-Dia (new) detected. DHTR #2- DAT negative, anti-Sda (new) detected, and cold agglutinin detected in serum. Historical anti-S and anti-Dia not seen. DHTR #3- DAT negative, anti-Sda reconfirmed. Historical anti-S, anti-Dia, and cold agglutinin not seen. Patient's current RBC antigen restrictions include: ABO/Rh compatible, CEK-, Fya-, Jkb-S-, Dia-, sickle-negative, crossmatch compatible units. HGB:Hemoglobin; ARC:Absolute Reticulocyte Count; LDH:Lactate Dehydrogenase; IVIg: Intravenous Immunoglobulin.

vation could have been caused either by DHTR, mycoplasma infection, or from a combination of the two in this case. Given her rapid improvement, eculizumab was not used during this episode.

Eight months later, the patient again presented with significant VOC pain and a HGB of 5.6 g/dL (Figure 1C), which dropped to 3.9 g/dL within 24 hours of admission (Figure 1C) in the absence of preceding RBC transfusion. Immunohematology testing reconfirmed the previous anti-Sda, but did not detect the previous anti-Dia, anti-S, or cold agglutinin. The DAT was negative. The patient received three units of extended phenotype-matched, crossmatch-compatible RBC units and was discharged home with an HGB of 9.5 g/dL. The patient presented again eight days later with generalized pain, fever, hemoglobinuria, and total hyperbilirubinemia of 7.3 mg/dL. Although her HGB was 11.0 g/dL on admission, it declined sharply (Figure 1C) with worsening of intravascular hemolysis reflected by elevated free plasma hemoglobin of 100 mg/dL, worsening hemoglobinuria, and LDH peak of 1753 U/L, along with elevated transaminases. DAT and antibody testing were again negative. A combination of immunosuppressive medications was initiated, including high dose steroids, IVIg and anti-CD20 antibody rituximab, as these along with erythropoietin have been previously used to help manage DHTR with life threatening hyperhemolysis.⁴ We completed 4-doses regimen of Rituximab to ensure adequate suppression of B lymphocytes and minimize the risk for relapse. In spite of these treatments, on day 14, the HGB declined to a nadir of 1.9 g/dL, creatinine doubled (Figure 1D), with

worsening symptoms of pain, altered mental status, and development of new diffuse pulmonary edema requiring positive airway pressure support. The blood smear was notable for occasional schistocytes. This episode of antibody-negative DHTR hyperhemolysis and multi-organ dysfunction prompted the administration of eculizumab 600mg intravenously along with transfusion of one unit (4 ml/kg) extended phenotype-matched and crossmatch-compatible RBCs. Within 48 hours, the patient's mental status improved remarkably, she reported less pain, hemolysis declined, and the patient was weaned off respiratory support. Concurrent complement analyses revealed increased levels of Bb, C5a, and C5b-9 (DHTR#3 day 13, Table 1), reflecting complement activation. On day 20, the patient was discharged and closely followed up in the clinic. On day 39, a second dose of eculizumab 600mg was administered for downward drift in HGB (nadir: 5.4 g/dL). Following this, the patient's HGB remained within her baseline range of 8-9 g/dL with no recurrence of laboratory evidence of hyperhemolysis. Steroids and erythropoietin were slowly weaned. The patient had received pneumococcal and meningococcal vaccinations as part of routine SCD standard-of-care and continued on a prophylactic antibiotic regimen during her treatment.

Currently, there is no consensus in the management of DHTR with ongoing hyperhemolysis in patients with SCD, when routine treatment measures are inadequate. This case highlights the potential contribution of ACP activation in DHTR hyperhemolysis. While new allo- and (cold) autoantibodies were identified during the second

DHTR episode, no new allo- or autoantibodies were detected during the third episode. Hyperhemolysis, organ dysfunction, and activation of ACP was present during the 3rd DHTR episode. The hemolysis associated with VOC, ACS or DHTR, results in elevated plasma heme, potentially saturating scavenging and detoxifying mechanisms of hemopexin and heme-oxygenase-1, respectively.^{6,7} Elevations in free heme would then be predicted to lead to additional endothelial damage, vaso-occlusion and activation of the alternative complement pathway, while inhibiting the classical pathway.⁸⁻¹¹ A case of antibody-negative DHTR in which eculizumab was used to dampen the complement activation was recently reported.¹² This and other reports have suggested the involvement of complement pathway in SCD and DHTR¹³⁻¹⁵; the present case is novel in that we employed sensitive markers to assess and confirm the activation of the ACP cascade during recurrent episodes of DHTR and at steady-state (*Online Supplementary Figure S1*). While these markers of the ACP do not necessarily shed light on the mechanism of ACP activation during DHTR, markedly elevated C5a, C5b-9 and most importantly Bb levels returned to normal levels as the patient recovered; plasma Bb levels provide a quantitative value of ACP activation. Plasma C3a levels were over 2.5 times above baseline but not over the normal range. Persistently elevated levels of CH50 even at day 127 could suggest continued low level baseline complement activation possibly due to ongoing chronic hemolysis. While the implementation of additional immunosuppressive therapies could have impacted this patient's outcome, the rapid response to eculizumab suggests that the reversal of hyperhemolysis may be due to the ability of eculizumab to block the downstream consequences of ACP. These laboratory and clinical findings strongly suggest that in this case, ACP was likely involved in DHTR with hyperhemolysis, and that ACP activation resolved after administration of eculizumab. However, as these are certainly correlative findings, definitive future studies are needed. As not all cases of DHTR may be accompanied by ACP activation or may benefit from eculizumab, analysis of ACP during DHTR episodes, especially when it is associated with hyperhemolysis and/or organ injury, may prove useful when assessing the potential benefit of eculizumab intervention. While additional studies are needed, including clinical assays that possess the ability to more completely assess complement function, early and appropriate administration of targeted therapy such as eculizumab may hold promise in the mitigation of potentially fatal complications in some patients. Future studies are needed to explore the mechanisms and potential role of prophylactic complement inhibition in patients with recurrent antibody-positive and antibody-negative DHTRs and those with minimal availability of antigen-compatible blood products.

Satheesh Chonat,^{1,2} Maa-Ohui Quarmyne,^{1,2}
 Caroline M. Bennett,^{1,2} Christina L. Dean,³
 Clinton H. Joiner,^{1,2} Ross M. Fasano^{3,5*} and Sean R. Stowell^{6*}

¹Department of Pediatrics, Emory University School of Medicine;
²Aflac Cancer and Blood Disorders Center, Children's Healthcare of Atlanta and ³Center for Transfusion and Cellular Therapy, Department of Pathology and Laboratory Medicine, Emory University School of Medicine, Atlanta, GA, USA.

*Senior authors contributed equally.

Correspondence: schonat@emory.edu
 doi:10.3324/haematol.2018.194670

Acknowledgments: the authors would like to thank the hematology and transfusion medicine teams at Children's Healthcare of Atlanta for their constructive review of the manuscript. No funding was used to conduct this study.

Information on authorship, contributions, and financial & other disclosures was provided by the authors and is available with the online version of this article at www.haematologica.org.

References

- Nickel RS, Horan JT, Fasano RM, et al. Immunophenotypic parameters and RBC alloimmunization in children with sickle cell disease on chronic transfusion. *Am J Hematol.* 2015;90(12):1135-1141.
- Vidler JB, Gardner K, Amenyah K, Mijovic A, Thein SL. Delayed haemolytic transfusion reaction in adults with sickle cell disease: a 5-year experience. *Br J Haematol.* 2015;169(5):746-753.
- Narbey D, Habibi A, Chadebecq P, et al. Incidence and predictive score for delayed hemolytic transfusion reaction in adult patients with sickle cell disease. *Am J Hematol.* 2017;92(12):1340-1348.
- Habibi A, Mekontso Dessap A, Guillaud C, et al. Delayed hemolytic transfusion reaction in adult sickle-cell disease: presentations, outcomes, and treatments of 99 referral center episodes. *Am J Hematol.* 2016;91(10):989-994.
- Pirenne F, Bartolucci P, Habibi A. Management of delayed hemolytic transfusion reaction in sickle cell disease: Prevention, diagnosis, treatment. *Transfus Clin Biol.* 2017;24(3):227-231.
- Ghosh S, Tan F, Yu T, et al. Global gene expression profiling of endothelium exposed to heme reveals an organ-specific induction of cytoprotective enzymes in sickle cell disease. *Voolstra C, editor. PLoS One.* 2011;6(3):e18399.
- Adisa OA, Hu Y, Ghosh S, Aryee D, Osunkwo I, Ofori-Acquah SF. Association between plasma free haem and incidence of vaso-occlusive episodes and acute chest syndrome in children with sickle cell disease. *Br J Haematol.* 2013;162(5):702-705.
- Roumenina LT, Radanova M, Atanasov BP, et al. Heme interacts with C1q and inhibits the classical complement pathway. *J Biol Chem.* 2011;286(18):16459-16469.
- Frimat M, Tabarin F, Dimitrov JD, et al. Complement activation by heme as a secondary hit for atypical hemolytic uremic syndrome. *Blood.* 2013;122(2):282-292.
- Ghosh S, Adisa OA, Chappa P, et al. Extracellular hemin crisis triggers acute chest syndrome in sickle mice. *J Clin Invest.* 2013; 123(11):4809-4820.
- Belcher JD, Chen C, Nguyen J, et al. Heme triggers TLR4 signaling leading to endothelial cell activation and vaso-occlusion in murine sickle cell disease. *Blood.* 2014;123(3):377-390.
- Dumas G, Habibi A, Onimus T, et al. Eculizumab salvage therapy for delayed hemolysis transfusion reaction in sickle cell disease patients. *Blood.* 2016;127(8):1062-1064.
- Gupta S, Fenves A, Nance ST, Sykes DB, Dzik WS. Hyperhemolysis syndrome in a patient without a hemoglobinopathy, unresponsive to treatment with eculizumab. *Transfusion.* 2014;55(3):623-628.
- Boonyasampant M, Weitz IC, Kay B, Boonchalemvichian C, Liebman HA, Shulman IA. Life-threatening delayed hyperhemolytic transfusion reaction in a patient with sickle cell disease: effective treatment with eculizumab followed by rituximab. *Transfusion.* 2015;55(10):2398-2403.
- Chonat S, Chandrakasan S, Kalinyak KA, Ingala D, Gruppo R, Kalfa TA. Atypical haemolytic uraemic syndrome in a patient with sickle cell disease, successfully treated with eculizumab. *Br J Haematol.* 2016;175(4):744-747.
- Stowell SR, Winkler AM, Maier CL, et al. Initiation and regulation of complement during hemolytic transfusion reactions. *Clin Dev Immunol.* 2012;2012:307093.