

Co-occurrence of CRLF2-rearranged and Ph⁺ acute lymphoblastic leukemia: a report of four patients

Ph-like acute lymphoblastic leukemia (Ph-like ALL) represents a high-risk subgroup of B-cell ALL.¹⁻⁷ By gene-expression, these patients have a profile similar to that of Ph⁺ ALL; however, they lack the BCR-ABL1 fusion. Patients with Ph-like ALL harbor a diverse range of genetic alterations activating tyrosine kinase signaling.³ Ph-like ALL comprise up to 15% of childhood B-ALL, and 20-25% of adolescent and young adult B-ALL.⁴ These patients have a very high rate of disease relapse and poor overall survival.^{4,8-10} Ph-like ALL and Ph⁺ ALL are thought to be mutually exclusive, and Ph-like ALL, by definition, does not have the Philadelphia chromosome.^{1,2,4} Rearrangements of CRLF2 are seen in approximately 50% of patients with Ph-like ALL. Co-occurrence of CRLF2-rearrangement and BCR-ABL1 fusion has been rarely described.^{11,12} We describe here four patients with co-occurrence of CRLF2 rearrangement and BCR-ABL1 fusion.

First patient: 26-year-old man of Hispanic ethnicity was diagnosed with B-ALL in May 2015 at an outside institution. Karyotype and FISH results were not available on the diagnostic bone marrow. He received 2 cycles of hyper-CVAD chemotherapy and had persistent disease. He was referred to MD Anderson Cancer Center (MDACC). At the time of his initial presentation to MDACC in August 2015, his white blood cell (WBC) count was 427,000/ μ L with 91% blasts in peripheral blood. Bone marrow showed 88% blasts. Flow cytometry immunophenotypic studies demonstrated that the neoplastic cells were positive for CD10 (bright), CD19, CD22, cytoplasmic CD79a, CD34, CD25 (partial), CD33 (partial), CD66c, HLA-DR, TdT, and negative for cytoplasmic IgM and myeloperoxidase, consistent with B-ALL. CRLF2 was positive in the blasts (*Online Supplementary Figure S1* and *Online Supplementary Table*

S1). A cryptic t(Y;14) was confirmed by metaphase FISH, and CRLF2 rearrangement was detected in 90% of interphases. JAK2 R683S mutation (mutant allele frequency 15.9%) was detected by next-generation sequencing that covered the entire coding region of JAK2. Two distinct NRAS mutations (G12D and G13D) were also detected at a low allelic frequency (<5%). Molecular testing was performed on total cellular DNA from bone marrow aspirates without separation of Ph⁺ and Ph⁻ cells. Unexpectedly, p190 (e1a2) PCR for BCR-ABL1 transcript (BCR-ABL1/ABL1 transcript ratio) was detected at a level of 76% using quantitative real-time reverse transcriptase PCR. Chromosomal analysis confirmed the t(9;22)(q34;q11.2). FISH for t(9;22)/BCR-ABL1 was positive in 56% of the cells. Sequential metaphase FISH confirmed the presence of CRLF2 rearrangement and BCR-ABL1 fusion in the same cell (Figure 1). Gene-expression profile (as previously described using LDA card^d), obtained on unsorted bone marrow aspirate, was consistent with Ph-like ALL. Thus, the patient had co-occurrence of Ph-like ALL (CRLF2-rearranged) with BCR-ABL1 fusion. Notably, BCR-ABL1 fusion was present in a subset of CRLF2-rearranged cells. The patient received salvage chemotherapy with hyper-CVAD and tyrosine kinase inhibitor ponatinib at 30mg orally daily dosing. After one cycle, the bone marrow blast count was reduced to 12% with complete resolution of Ph⁺ clone (negative FISH and RT-PCR for BCR-ABL1); however, the CRLF2-rearranged clone persisted. The patient received cycle 2 of hyper-CVAD regimen with methotrexate and cytarabine, ponatinib was continued, and JAK2 inhibitor ruxolitinib (15mg orally twice daily) was added to suppress the JAK2-mutated CRLF2⁺ clone. However, after cycle 2 the marrow showed rising blast count with 48% blasts. Ph⁺ clone remained undetectable whereas the CRLF2⁺ clone persisted (*Online Supplementary Table S1*). The patient then received alternative salvage chemotherapy (fludarabine, cytarabine, pegylated asparaginase, vincristine, and dexamethasone); unfortunately, this was

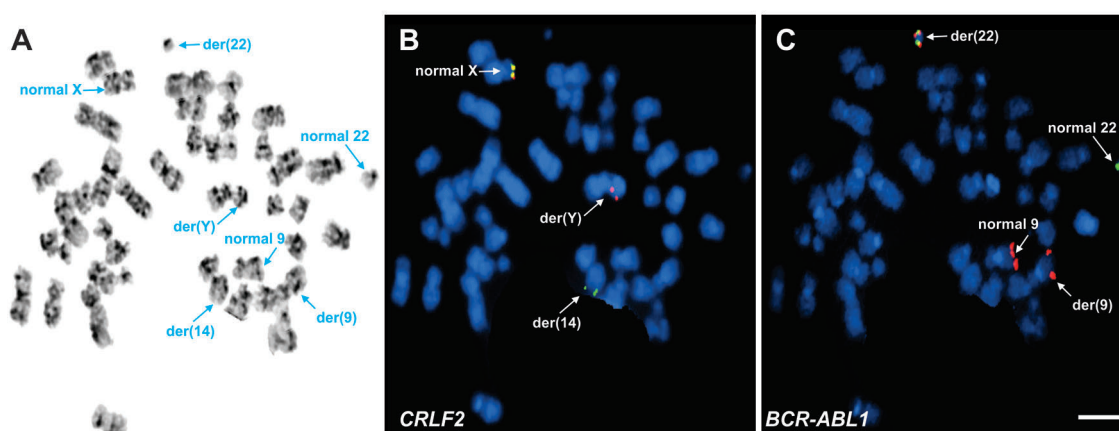


Figure 1. FISH was conducted using a dual color break apart probe set for the CRLF2 gene and a dual color extra signal translocation probe for BCR/ABL1 sequentially on a G-banded metaphase spread. A: G-banded metaphase showing a t(9;22), the t(Y;14) is cryptic and not visible by chromosomal analysis. B: First FISH on the G-banded metaphase using the CRLF2 breakapart probe revealed the t(Y;14) showing a red signal on the abnormal Y/der(Y) and a green signal on the abnormal 14/der(14). The X chromosome showing a normal yellow signal for the CRLF2 gene. C: Second FISH on the same metaphase using the BCR/ABL1 probe set confirmed the BCR-ABL1 yellow fusion signal on the Ph⁺ chromosome/der(22). The normal 9 showing a large red signal (ABL1) and the abnormal 9 showing a smaller red signal (ABL1), the normal 22 showing a green signal (BCR).

complicated by multi-drug resistant pseudomonas sepsis leading to multi-organ failure, and patient's death.

Second patient: 21-year-old man of Hispanic ethnicity was diagnosed with B-ALL in June 2014 at an outside institution. Karyotype was diploid and *BCR-ABL1* FISH was negative. He received 6 cycles of hyper-CVAD chemotherapy with rituximab; unfortunately, his disease relapsed (Dec 2014), and he was referred to MDACC. The bone marrow showed 41% blasts. Flow cytometry immunophenotypic studies demonstrated that the neoplastic cells were positive for CD10 (bright), CD19, CD22, cytoplasmic CD79a, CD25 (small subset), CD33 (partial), CD34, CD66c (small subset), HLA-DR, TdT and negative for cytoplasmic IgM and myeloperoxidase. The blasts were positive for CRLF2 (*Online Supplementary Figure S1* and *Online Supplementary Table S1*). FISH and RT-PCR for *BCR-ABL1* were negative, and conventional cytogenetics showed a complex karyotype. The patient was treated with blinatumomab without a response. He received salvage chemotherapy with clofarabine, etoposide, cyclophosphamide, liposomal vincristine, bortezomib, and steroids, and achieved CR. He then underwent haplo-identical stem cell transplant (SCT) with fludarabine, melphalan, and thiotepa conditioning, followed by donor-derived CAR-T cell infusion. Unfortunately, bone marrow done day 100 post-SCT showed disease relapse with 83% blasts. CRLF2 expression was again detected by flow cytometry, a split signal of CRLF2 (green) was detected on chromosome 14 by a metaphase FISH, and CRLF2 rearrangement was detected in 88% of the cells. Gene-expression profile was consistent with Ph-like ALL. *JAK2* mutation was not detected. *PTPN11* mutation was detected at a low allelic frequency (<5%). Unexpectedly, RT-PCR for *BCR-ABL1* p190 (e1a2) transcript was positive (6.2%). Additionally, FISH for *BCR-ABL1* was positive (4%). Thus, the patient had co-occurrence of Ph-like ALL (CRLF2-rearranged) with *BCR-ABL1* fusion. Notably, *BCR-ABL1* fusion was not present at the time of initial presentation, and was acquired at the time of disease relapse post-SCT. The patient was started

on chemotherapy with EPOCH and ponatinib 30mg daily was added. After one cycle, bone marrow showed persistent disease with 91% blasts. Similar to the clinical course of the first patient, there was a clearance of Ph+ clone (negative by both PCR and FISH); however, the CRLF2+ clone persisted (*Online Supplementary Table S1*). The patient then received a salvage chemotherapy regimen (methotrexate, vincristine, pegylated asparaginase, dexamethasone), ponatinib was continued, and ruxolitinib 15mg twice daily was added to suppress the CRLF2+ clone. Unfortunately, after cycle 2 the marrow showed persistent disease with 37% marrow blasts. Ph+ clone remained undetectable; CRLF2+ clone persisted. The patient developed intracranial hemorrhage in the setting of thrombocytopenia leading to his death.

Third patient: 14-year-old boy of Hispanic ethnicity was diagnosed with B-ALL in July 2016 and was referred to MDACC. His WBC count was 37,400/ μ L with 83% blasts in the peripheral blood. Bone marrow showed 82% blasts. Flow cytometry immunophenotypic studies demonstrated that the neoplastic cells were positive for CD10, CD19, CD20 (partial), CD22, cytoplasmic CD79a, CD25 (partial), CD33 (partial), CD34, CD66c, CRLF2 (*Online Supplementary Figure S1*), HLA-DR, TdT, and negative for cytoplasmic IgM and myeloperoxidase. CRLF2 rearrangement was confirmed by a metaphase FISH with deletion of proximal CRLF2 (partial deletion of chromosome Xp22.33), and this was observed in 56% of interphases. Three different mutations in *JAK2* (*JAK2* R683S, *JAK2* R867Q, *JAK2* L884P), all at a low allele burden (<5%) were detected. Chromosomal analysis showed presence of Philadelphia chromosome. FISH for t(9;22) was positive in 21% of the cells. *BCR-ABL1* transcript p190 (e1a2) was detected at a level of 48% using RT-PCR. Sequential metaphase FISH confirmed the presence of CRLF2 rearrangement and *BCR-ABL1* fusion in the same cell (*Figure 2*). Thus, the patient had co-occurrence of CRLF2-rearrangement and *BCR-ABL1* fusion. The patient received induction therapy with a pediatric regimen in combination with dasatinib. After induction, he

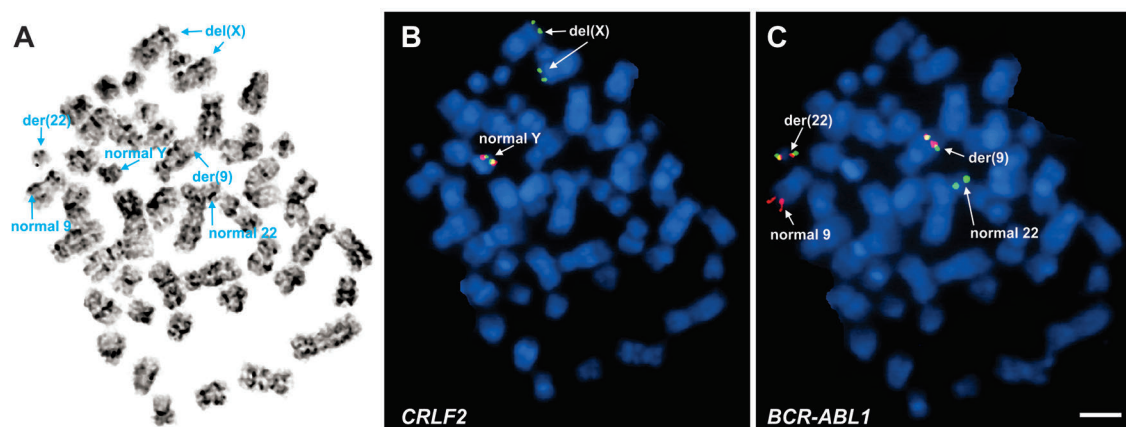


Figure 2. FISH was conducted using a dual color break apart probe set for the *CRLF2* gene and a dual color extra signal translocation probe for *BCR/ABL1* sequentially on a G-banded metaphase spread. A: A G-banded metaphase showing t(9;22)(q34;q11.2), a normal chromosome Y, and two morphologically normal chromosome X (with cryptic deletion of Xp22.33). B: First FISH on the same metaphase using the *CRLF2* breakapart probe revealed the del(X) showing a green signal on both X chromosomes and a normal yellow signal for the *CRLF2* gene on the Y chromosome. C: Sequential FISH on the same metaphase using the *BCR/ABL1* probe set confirmed the *BCR-ABL1* showing two yellow fusion signals on the Ph+ chromosome or the der(22) and the der(9), respectively. The normal 9 showed a red signal (*ABL1*) and the normal 22 showed a green signal (*BCR*).

achieved CR with minimal residual disease (MRD) positivity by flow-cytometry (*Online Supplementary Table S1*). BCR-ABL1 RT-PCR was 0.01%. A follow-up marrow showed CR with MRD negativity and undetectable BCR-ABL1 RT-PCR. Patient continues to be in remission and is receiving consolidation chemotherapy with a follow up of 8 months.

Fourth patient: 23-year-old man of Hispanic ethnicity was diagnosed with B-ALL in February 2017 and was referred to MDACC. His WBC count was 125,200/ μ L with 95% blasts in the peripheral blood. Bone marrow showed 93% blasts. Flow cytometry immunophenotypic studies demonstrated that the neoplastic cells were positive for CD10, CD19, CD20 (partial), CD22 (partial), cytoplasmic CD79a, CD25, CD33 (partial), CD13 (partial), CD34, HLA-DR, TdT, and negative for myeloperoxidase. The B-ALL cells were positive for CRLF2. CRLF2 positivity was confirmed by interphase FISH (94% cells positive). *JAK2* R683S mutation was detected. Chromosomal analysis showed presence of Philadelphia chromosome. FISH for t(9;22) was positive in 91% of the cells. BCR-ABL1 transcript p190 (e1a2) was detected. The patient was diagnosed with Ph+ ALL with CRLF2-rearrangement. The patient received induction therapy with hyper-CVAD chemotherapy in combination with ponatinib. After induction, he achieved CR with MRD positivity (*Online Supplementary Table S1*). BCR-ABL1 RT-PCR was 5.8%. A follow-up marrow showed CR with continued MRD positivity. Patient continues to be in remission and is receiving consolidation chemotherapy with a follow up of 2 months.

Ph-like ALL is a high-risk subgroup of B-ALL, and is considered mutually exclusive of Ph+ ALL. We report here four patients with co-occurrence of CRLF2-rearrangement with *BCR-ABL1* fusion. By metaphase FISH analysis, we were able to show the presence of CRLF2 rearrangement and *BCR-ABL1* translocation in the same leukemic cell in two patients (Figures 1 and 2). The first two patients were young men, both of Hispanic ethnicity, and were treated in a similar fashion. In patient 1, although we did not have the baseline information of the B-ALL, FISH studies at MDACC showed >90% cells with CRLF2 rearrangement and a subset of cells (56%) with *BCR-ABL1* rearrangement. In patient 2, Ph+ clone was small (6.2%), and only detected at the time of relapse. Both had eradication of the Ph+ clone with the use of ponatinib, an established therapy for Ph+ ALL. However, CRLF2+ clone persisted. These findings suggest that CRLF2 rearrangement is an early event and *BCR-ABL1* fusion may occur as a secondary event. Future studies on a single-cell level are needed to analyze the clonal evolution and hierarchy.^{13,14} For the third and fourth patient, we were able to show presence of both CRLF2 rearrangement and *BCR-ABL1* translocation at the time of original diagnosis. Both these patients have responded to tyrosine kinase inhibitors in combination with chemotherapy.

As patients with CRLF2+ ALL have overactivation of JAK-STAT pathway,^{3,15} ruxolitinib, an inhibitor of JAK-STAT pathway, was added to the treatment regimen of the first two patients; however, both failed to respond, and eventually died from disease-related complications. Both patients received ruxolitinib at 15 mg twice daily, the starting dose in an ongoing phase II clinical trial with ruxolitinib in patients with Ph-like ALL at our center (NCT02420717). It is possible that a higher dose of ruxolitinib may be required for optimal inhibition of JAK-STAT signaling in patients with Ph-like ALL overexpressing CRLF2, as often utilized in pediatric patients with Ph-like ALL.¹⁶ JAK inhibition with novel type II JAK

inhibitors which stabilizes *JAK2* in an inactive conformation have shown to suppress the growth of CRLF2+ B-ALL cells, and could be explored therapeutically.^{17,18} TSLPR-targeted CAR T-cell strategy to target the CRLF2 clone represents another potential therapy option.¹⁹ Further studies evaluating the biology of resistance in CRLF2+ Ph-like ALL are warranted.

Nitin Jain,¹ Xinyan Lu,² Naval Daver,¹ Beenu Thakral,² Sa A. Wang,² Sergej Konoplev,² Keyur Patel,² Rashmi Kanagal-Shamanna,² Marcus Valentine,³ Guilin Tang,² Naveen Pemmaraju,¹ Jeffrey Jorgensen,² Partow Kebriaei,⁴ Cesar A. Nunez,⁵ William Wierda,¹ Elias Jabbour,¹ Kathryn G. Roberts,³ Charles G. Mullighan,³ Hagop Kantarjian¹ and Marina Konopleva¹

¹Department of Leukemia, The University of Texas M.D. Anderson Cancer Center, Houston, TX; ²Department of Hematopathology, The University of Texas M.D. Anderson Cancer Center, Houston, TX; ³Department of Pathology, St. Jude Children's Research Hospital, Memphis, TN; ⁴Department of Stem Cell Transplantation, The University of Texas M.D. Anderson Cancer Center, Houston, TX and ⁵Department of Pediatrics, The University of Texas M.D. Anderson Cancer Center, Houston, TX, USA

Funding: this work was supported in part by the Cancer Prevention and Research Institute of Texas (CPRIT) Grant RP150006 "Defining and Treating Targetable Lesions in AYA Acute Lymphoblastic Leukemia".

Correspondence: mkonoplev@mdanderson.org
doi:10.3324/haematol.2016.161000

Information on authorship, contributions, and financial & other disclosures was provided by the authors and is available with the online version of this article at www.haematologica.org.

References

- Den Boer ML, van Slegtenhorst M, De Menezes RX, et al. A subtype of childhood acute lymphoblastic leukaemia with poor treatment outcome: a genome-wide classification study. *Lancet Oncol*. 2009;10(2):125-134.
- Mullighan CG, Su X, Zhang J, et al. Deletion of IKZF1 and prognosis in acute lymphoblastic leukemia. *N Engl J Med*. 2009;360(5):470-480.
- Roberts KG, Morin RD, Zhang J, et al. Genetic alterations activating kinase and cytokine receptor signaling in high-risk acute lymphoblastic leukemia. *Cancer Cell*. 2012;22(2):153-166.
- Roberts KG, Li Y, Payne-Turner D, et al. Targetable kinase-activating lesions in Ph-like acute lymphoblastic leukemia. *N Engl J Med*. 2014;371(11):1005-1015.
- Arber DA, Orazi A, Hasserjian R, et al. The 2016 revision to the World Health Organization classification of myeloid neoplasms and acute leukemia. *Blood*. 2016;127(20):2391-2405.
- Roberts KG, Gu Z, Payne-Turner D, et al. High frequency and poor outcome of Philadelphia chromosome-like acute lymphoblastic leukemia in adults. *J Clin Oncol*. 2017;35(4):394-401.
- Jain N, Roberts KG, Jabbour E, et al. Ph-like acute lymphoblastic leukemia: a high-risk subtype in adults. *Blood*. 2017;129(5):572-581.
- Harvey RC, Mullighan CG, Chen IM, et al. Rearrangements of CRLF2 is associated with mutation of JAK kinases, alteration of IKZF1, Hispanic/Latino ethnicity, and a poor outcome in pediatric B-progenitor acute lymphoblastic leukemia. *Blood*. 2010;115(26):5312-5321.
- Harvey RC, Mullighan CG, Wang X, et al. Identification of novel cluster groups in pediatric high-risk B-precursor acute lymphoblastic leukemia with gene expression profiling: correlation with genome-wide DNA copy number alterations, clinical characteristics, and outcome. *Blood*. 2010;116(23):4874-4884.
- Cario G, Zimmermann M, Romey R, et al. Presence of the P2RY8-CRLF2 rearrangement is associated with a poor prognosis in non-high-risk precursor B-cell acute lymphoblastic leukemia in children treated according to the ALL-BFM 2000 protocol. *Blood*. 2010;115(26):5393-5397.
- Schwab CJ, Chilton L, Morrison H, et al. Genes commonly deleted in childhood B-cell precursor acute lymphoblastic leukemia: association with cytogenetics and clinical features. *Haematologica*. 2013;98(7):1081-1088.

12. Russell LJ, Enshaei A, Jones L, et al. IGH@ translocations are prevalent in teenagers and young adults with acute lymphoblastic leukemia and are associated with a poor outcome. *J Clin Oncol*. 2014;32(14):1453-1462.
13. Jeffries SJ, Jones L, Harrison CJ, Russell LJ. IGH@ translocations co-exist with other primary rearrangements in B-cell precursor acute lymphoblastic leukemia. *Haematologica*. 2014;99(8):1334-1342.
14. Turati VA, Guerra-Assunção JA, Ambrose JC, et al. Single-cell analysis of clonal dynamics in childhood ALL reveals a key role for transcriptional intratumor heterogeneity in driving resistance to chemotherapy. *Blood*. 2016;128(22):606.
15. Tasian SK, Doral MY, Borowitz MJ, et al. Aberrant STAT5 and PI3K/mTOR pathway signaling occurs in human CRLF2-rearranged B-precursor acute lymphoblastic leukemia. *Blood*. 2012;120(4):833-842.
16. Loh ML, Tasian SK, Rabin KR, et al. A phase 1 dosing study of ruxolitinib in children with relapsed or refractory solid tumors, leukemias, or myeloproliferative neoplasms: A Children's Oncology Group phase 1 consortium study (ADVL1011). *Pediatr Blood Cancer*. 2015;62(10):1717-1724.
17. Wu SC, Li LS, Kopp N, et al. Wu SC, Li LS, Kopp N, et al. Activity of the type II JAK2 inhibitor CHZ868 in B cell acute lymphoblastic leukemia. *Cancer Cell*. 2015;28(1):29-41.
18. Meyer SC, Keller MD, Chiu S, et al. CHZ868, a Type II JAK2 Inhibitor, Reverses Type I JAK Inhibitor Persistence and Demonstrates Efficacy in Myeloproliferative Neoplasms. *Cancer Cell*. 2015; 28(1):15-28.
19. Qin H, Cho M, Haso W, et al. Eradication of B-ALL using chimeric antigen receptor-expressing T cells targeting the TSLPR oncoprotein. *Blood*. 2015;126(5):629-639.