

## Use of bortezomib in the management of chronic graft-versus-host disease among multiple myeloma patients relapsing after allogeneic transplantation

**We report on the use of bortezomib for the management of chronic graft versus host disease (cGVHD) among 8 multiple myeloma (MM) patients who relapsed after reduced-intensity conditioning (RIC) allogeneic transplantation. Five patients (62%) responded to bortezomib demonstrating anti-myeloma effect. Four patients had active cGVHD, including 3 patients with severe punctate keratopathy, at the time of bortezomib administration. All showed an improvement in their condition. This is the first report showing that bortezomib may be useful in the management of cGVHD and related ocular involvement.**

*Haematologica* 2007; 92:1295-1296. DOI: 10.3324/haematol.10820

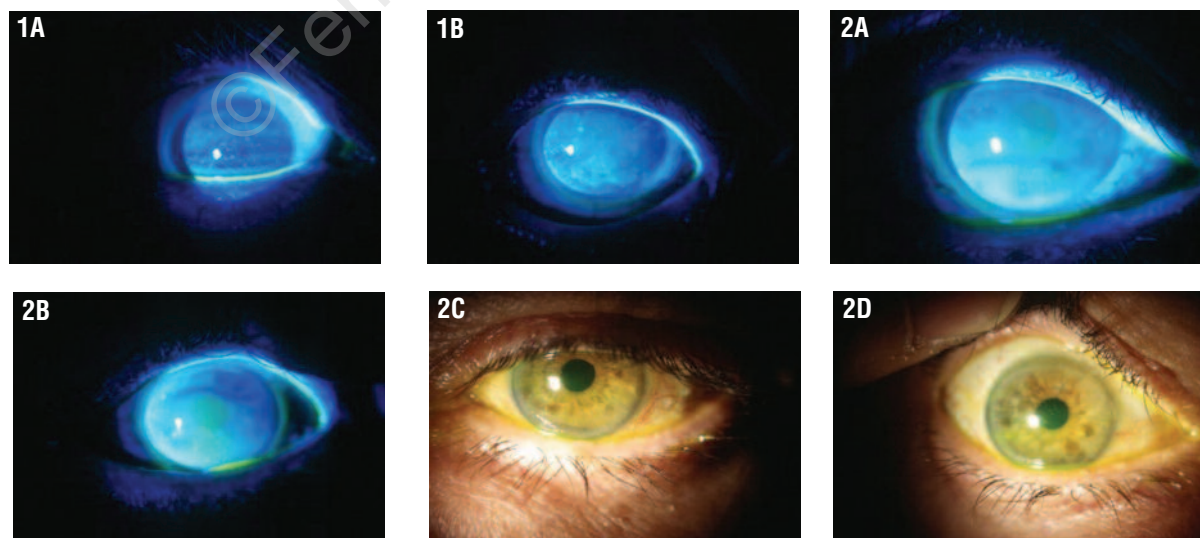
We report on the use of bortezomib for the treatment of 8 MM patients who relapsed after allo-RIC. Median age was 54.5 years (range: 30-62). Relapses occurred at a median of 15 months (range: 3-33). Five patients developed an extramedullary relapse and in the remaining 3 patients an increase of monoclonal component was also observed. Two showed bone marrow infiltration > 10% plasma cells by flow cytometry while in the remaining 6 patients no infiltration was observed in the bone marrow. Prior to bortezomib, 3 patients received a mean of 3 donor lymphocyte infusions (range 2-4) at a starting dose of  $1 \times 10^7$  CD3<sup>+</sup> cells/kg. Other therapeutic strategies prior to bortezomib included Tha-Cy-Dex in one patient and thalidomide as a single agent in another patient. Bortezomib was administered at conventional doses for a median of 6 cycles (range 3-12). Three patients received bortezomib alone, two in combination with dexametasone, one in combination with liposomal doxorubicin, and two patients also received local radiotherapy to treat extramedullary relapses. Five patients (62%) responded, including 2 (25%) complete responses

(CR). Both of them are in CR 8 to 12 months after treatment respectively. One out of the 3 patients who reached partial response (PR) continues in PR six months after treatment while the other two patients progressed. All 3 patients are, however, alive 6 to 43 months after relapse. Three patients (37%) did not respond to treatment. One of them is alive 3 months after relapse.

Among observed toxicity, the most secondary effects were neuropathy, affecting 5 (62%) patients. Grades III/IV thrombocytopenia were observed in 4 (50%) patients, leukopenia in 1 (12%) while 4 (50%) patients had gastrointestinal toxicity. Four patients (50%) did not receive the 8 planned cycles and required drug discontinuation due to grades III/IV neuropathy (2 patients), headache (1 patient), and grade III/IV cytopenias (1 patient).

Four patients had chronic and one acute GVHD at the time of bortezomib administration with severe punctate keratopathy in three patients. Systemic immunosuppression was already stopped at the time of MM relapse in 3 patients while 1 patient was still being tapered off tacrolimus. Interestingly, in all four patients, cGVHD significantly improved.

A median of 150 days (range: 120-333 days) after bortezomib discontinuation, cGVHD continues in remission in three patients. Interestingly both symptoms and conjunctival ulcerations responded in all 3 patients with ocular involvement (Figure 1). However, in 1 of them, the punctate keratopathy has reappeared at last follow-up. The patient with aGVHD developed scleroderma at the time of bortezomib treatment. Bortezomib is a useful drug in the treatment of relapsed MM, including extramedullary involvement.<sup>1-3</sup> We focused on the influence of bortezomib on the outcome of cGVHD. Therefore, four patients with refractory extensive (n=3) or limited (n=1) cGVHD responded to bortezomib. However, since two of these patients also received dexametasone, GVHD response could be attributed to any of the two agents. Nevertheless, one of these patients had already received dexametasone in combination with thalidomide and cyclophosphamide and neither MM nor cGVHD had responded. For the remaining patient,



**Figure 1.** In patient 1, at physical examination ocular involvement improved from grade 4 and 5 keratitis prior to bortezomib to total recovery of the ocular surface after treatment. Pre-bortezomib findings: (1A) Right eye: fluorescein staining (grade 4 keratitis according to Oxford scale); (1B) Left eye: fluorescein staining (grade 5 keratitis); post-bortezomib findings: (2A) Right eye. No fluorescein staining (grade 0); (2B) Left eye. No fluorescein staining (grade 0); (2C) right eye and (2D) Left eye: anterior segment biomicroscopy; no hyperemia, no keratitis, no epithelial defects.

**Table 1.** Patients' characteristics and outcome.

Nº	Gender and age	Treatment	Response to bortezomib	GvHD	Previous immunosuppressive treatment	Immunosuppression at the time of bortezomib administration	GvHD outcome after bortezomib	Follow-up
1	M/58 years	Bortezomib x6 + RT	CR	cGVHD (extensive)*	Tacrolimus + prednisone	Tacrolimus being tapered off plus topic treatment	Improvement	+ 4y + 6m.
2	M/45 years	Bortezomibx3 <sup>a</sup> + RT	CR	cGVHD (limited)	Topic treatment	Topic treatment	improvement	+ 3y + 9m.
3	F/58 years	Bortezomibx7 <sup>a</sup> + Dex	PR	cGVHD (extensive)*	Tacrolimus plus topic treatment	Topic treatment	improvement	+ 4y + 9 m.
4	F/30 years	Bortezomibx8 + Dex	PD	cGVHD (extensive)*	Cyclosporine plus topic treatment	Topic treatment	improvement	+ 2y + 10m.
5	M/57 years	Bortezomibx5 <sup>a</sup> + Doxil	PR	None				+ 3y
6	M/47 years	Bortezomibx13	PR	None				+ 6y + 1m.
7	F/62 years	Bortezomibx7	PD	None				14m (died)
8	F/52 years	Bortezomibx4	PD	aGVHD		None	Progression.	9m. (died)

CR: complete remission; PR: partial response; PD: progressive disease; GVHD: graft-versus-host disease; cGVHD: chronic GVHD. (\*) ocular involvement; <sup>a</sup>Immunosuppressive therapy could be stopped; RT: local radiotherapy; Dex: dexamethasone.

cGVHD improvement could be related to both bortezomib and/or dexamethasone. By contrast patient 1, who responded to bortezomib alone, had previously received prednisone in combination with tacrolimus and cGVHD had not improved. This further suggests the efficacy of bortezomib independently of the steroid administration. Improvement at the ocular level is remarkable since ocular involvement is usually very resistant to conventional treatment, including steroids.<sup>4,5</sup> Although other chemotherapeutic agents may induce a less specific immunosuppression, bortezomib modulates immune responses inducing selective apoptosis among alloreactive T cells.<sup>6,7</sup> Interestingly, several studies have shown that NF-κB activation plays a crucial role in inflammatory eye disease. NF-κB blockade may, therefore, have an important role in the management of ocular GVHD.<sup>8</sup> Interestingly, GVHD and graft-versus-myeloma effect are closely associated with allo-RIC. Nevertheless, myelomatous cells may escape GVM control outside bone marrow increasing the risk of extramedullary relapses even among patients who develop cGVHD.<sup>9</sup> The efficacy of bortezomib in the treatment of extramedullary relapses and its effect on GVHD suggests it may help to control GVHD without compromising GVM. However, bortezomib must be carefully monitored after allogeneic transplantation because in this study, 62% patients developed neuropathy requiring drug discontinuation in 2 patients. Results from previous clinical studies are very limited and even contradictory. Giralt *et al.*<sup>10</sup> reported that bortezomib did not worsen cGVHD in a series of 9 patients while Kröger *et al.* reported a mild aggravation of skin GVHD in two patients with cGVHD and in one patient with aGVHD among 18 MM patients.<sup>2</sup>

Although this is a short series of patients, it is the first report showing that bortezomib may be useful in the management of cGVHD, and its related ocular involvement.

Juan Mateos-Mazon, José-Antonio Pérez-Simón, Olga Lopez, Emiliano Hernández,\* Jaime Etxebarria,° Jesús F. San Miguel  
Servicio de Hematología y Oftalmología,\* Hospital Clínico Universitario de Salamanca and Servicio de Oftalmología,° Hospital de Cruces, Bilbao, Spain

Key words: cGVHD, multiple myeloma, bortezomib, allogeneic transplant.

Correspondence: J.A. Pérez-Simón, MD, PhD, Servicio de Hematología, Hospital Clínico Universitario de Salamanca, Paseo de San Vicente s/n 37007, Salamanca, Spain. Fax: international 34-923-294624. Phone: international +34.923.291316. E-mail: pesimo@usal.es

## References

- Rosiñol L, Cibeira MT, Uriburu C, Yantorno S, Salamero O, Bladé J, et al. Bortezomib: an effective agent in extramedullary disease in multiple myeloma. *Eur J Haematol* 2006;76:405-8.
- Kröger N, Zabelina T, Ayuk F, Atanackovic H, Schieder H, Renges H, et al. Bortezomib after dose-reduced allogeneic stem cell transplantation for multiple myeloma to enhance or maintain remission status. *Experimental haematology* 2006;34:770-5.
- Van de Donk NW, Kroger N, Hegenbart U, Corradini P, San Miguel JF, Goldschmidt H, et al. Remarkable activity of novel agents bortezomib and thalidomide in patients not responding to donor lymphocyte infusions following nonmyeloablative allogeneic stem cell transplantation in multiple myeloma. *Blood* 2006;107:3415-6.
- Filipovich A, Weisdorf D, Pavletic S, Socie G, Wingard J, Lee S, et al. National Institutes of Health Consensus Development Project on Criteria for Clinical Trials in Chronic Graft-versus-Host Disease: I. Diagnosis and Staging Working Group Report. *Biology of Blood and Marrow Transplantation* 2005;11:945-55.
- Pavletic S, Martin P, Lee S, Mitchell S, Jacobsohn D, Cowen E, et al. Measuring therapeutic response in chronic graft-versus-host disease: National Institutes of Health Consensus Development Project on Criteria for Clinical Trials in Chronic Graft-versus-Host Disease: IV. Response Criteria Working Group report. *Biol Blood Marrow Transplant* 2006;12:252-66.
- Blanco B, Perez-Simon JA, Sanchez-Abarca LI, Carvajal-Vergara X, Mateos J, Vidriales B, et al. Bortezomib induces selective depletion of alloreactive T lymphocytes and decreases the production of TH1 cytokines. *Blood* 2006; 107:3575-83.
- Sun K, Welniak LA, Panoskaltis-Mortari A, O'Shaughnessy M, Liu H, Barao I et al. Inhibition of acute graft-versus-host disease with retention of graft-versus-tumor effects by the proteasome inhibitor bortezomib. *Proc Natl Acad Sci USA* 2004;101:8120-5.
- Wang XC, Jobin C, Allen JB, Roberts WL, Jaffe GJ. Suppression of NF-KB-Dependent proinflammatory gene expression in human RPE cells by proteasome inhibitor. *Invest Ophthalmol Vis Sci* 1999;40:477-86.
- Pérez-Simón J, Sureda A, Fernández-Avilés F, Sampol A, Cabrera J, Caballero D, et al. Reduced intensity conditioning allogeneic transplantation is associated with a high incidence of extramedullary relapses in multiple myeloma patients. *Leukemia* 2006;20:542-5.
- Giralt S, Aleman A, Lei X, Davis M, Mickler K, Weber D, et al. Results of Bortezomib therapy for myeloma patients relapsing after an allogeneic transplant. Preliminary results show efficacy without induction of GVHD. *Blood* 2004; 104:#1651[Abstrat].