

Management of Life-Threatening Pulmonary Leukostasis with Single Agent Imatinib Mesylate during CML Myeloid Blast Crisis

Pulmonary leukostasis is a rare but serious and often fatal complication of chronic myeloid leukemia (CML) in blast crisis and acute myeloid leukemia. Treatment options are limited for these patients. Imatinib mesylate (STI-571, Gleevec, Novartis) is a potent and selective inhibitor of the BCR-abl tyrosine kinase, the molecular abnormality that causes CML. The case of a 74-year-old man with a history of CML who presented in myeloid blast crisis with pulmonary leukostasis characterized by increasing dyspnea, hypoxemia, fever, and impending respiratory failure is reported. The patient was treated with single agent imatinib mesylate (IM) with rapid decrease in his white blood cell count (WBC) and marked improvement in his respiratory status. No electrolyte abnormalities consistent with tumor lysis syndrome were observed. IM may be an effective single agent therapy for pulmonary leukostasis in patients with CML blast crisis who are at the risk for tumor lysis.

Haematologica 2004; 89:(8)e102-e103

Patients with acute myeloid leukemia (AML) or CML in myeloid blast crisis who present with hyperleukocytosis have a poor prognosis, due primarily to early death from severe pulmonary and neurologic complications. Pulmonary leukostasis, microcirculatory failure from sludging of leukemic blasts in lung capillary vessels, has been identified as the single worst prognostic factor in patients with hyperleukocytosis.¹ Despite significant advances in treatment regimens and supportive care there has been little improvement in outcomes in this patient population. Only 5 of 19 patients (26.3%) presenting with pulmonary leukostasis and treated with leukopheresis, hydroxyurea, and induction chemotherapy survived during the first week of treatment in one recent study.^{2,3}

Imatinib mesylate (IM) a specific inhibitor of the bcr/abl tyrosine kinase, has been shown to have significant activity in patients with CML myeloid blast crisis.^{4,5} IM induced hematologic responses in 52% of CML myeloid blast crisis patients although complete hematologic responses were reported in less than 10%. IM has the ability to rapidly and safely cytoreduce patients with CML blast crisis. Median times to normalization of white blood cell count (WBC) and clearance of peripheral blasts in patients with CML myeloid blast crisis were 8.5 days and 16 days respectively (Karamlou, personal communication). This report describes a patient with CML myeloid blast crisis and life threatening pulmonary leukostasis who rapidly responded to IM with decrease in his WBC and marked improvement of his respiratory failure.

Case Report

A 74-year-old man with a nine-year history of stable phase CML, previously treated with hydroxyurea and anagrelide, presented to our institution with myeloid blast crisis for enrollment on a phase I IM trial. On screening evaluation, he was noted to be a frail appearing elderly man in no acute distress with a respiratory rate of 18 breaths per minute. Over the subsequent 24 to 48 hours, he developed marked increased dyspnea, hypox-

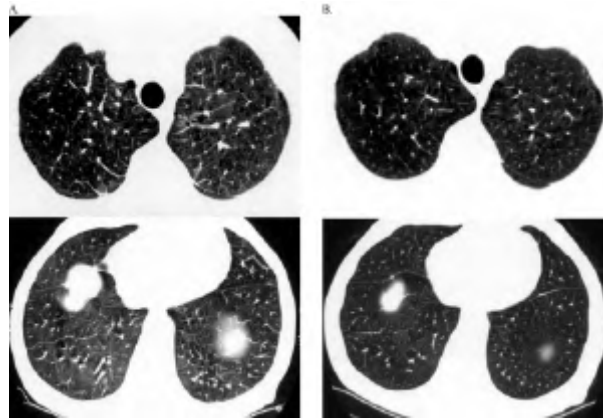


Figure 1. Radiological Manifestations of Pulmonary Leukostasis resolve after Imatinib Therapy. Increased diffuse bilateral reticulation or linearity resembling interstitial edema or lymphangitic carcinomatosis on computed tomography of the chest (A). Findings resolve after initiation of treatment with imatinib (B).

emia (oxygen saturation of 88%) on room air and a low grade fever. On physical examination, the patient was in marked respiratory distress with labored breathing, clear lung fields on auscultation and percussion, and marked hepatosplenomegaly. Laboratory studies revealed a WBC of 125,000 per microliter with 28% circulating myeloblasts and 8% basophils, and elevated uric acid, phosphate, and LDH levels. Chest x-rays showed increased interstitial markings but no focal consolidation. The patient was diagnosed with impending respiratory failure and admitted to the Leukemia Service. Examination of the bone marrow showed a markedly hypercellular marrow with 43% myeloblasts (CD13 and CD34+ with partial expression of CD19, CD33, CD79a, and myeloperoxidase) and 18% basophilia. Due to his low-grade fever, the patient had multiple cultures and a high resolution CT scan of the chest that showed scattered bilateral thickening of the intralobular septa with patchy areas of ground glass opacity but no focal lung consolidation (see Figure 1A). The patient was started on 40% oxygen via face mask, antibiotics, and IM at a dose of 500 mg bid. A bronchoalveolar lavage was performed and all subsequent cultures were negative. Within 48 hours there was a significant decrease in his WBC and marked improvement in his respiratory status. No evidence of tumor lysis syndrome occurred (Table 1). Follow-up CT scan of the chest showed interval resolution of the intralobular septal thickening and vascular congestion (Figure 1B). The patient was discharged to home four days after admission and continued on IM for six months until time of relapse.

Discussion

Pulmonary leukostasis has been identified as the single worst prognostic factor in patients presenting with hyperleukocytosis of either acute myeloid leukemia or CML in myeloid blast crisis.

Despite significant improvements in leukemia treatment regimens and supportive care, the outcome of patients with pulmonary leukostasis has not improved significantly over the past two decades and median survivals of less than one week are common.^{1-3,6,7} As in this case, many patients present with respiratory distress, hypoxemia, diffuse interstitial infiltrates on pulmonary radiographs, and fever. Current treatment focuses on aggressive supportive care and upon cytoreduction with

Table 1. Lack of Tumor Lysis During Imatinib Therapy for CML Blast Crisis.

Day of Therapy	WBC (K/ μ l)	Blasts (%)	Platelet (K/ μ l)	Creatinine (mg/dL)	Potassium (mmol/L)	Phosphorous (mg/dL)	Acid (mg/dl)	LDH (U/L)
-2	99.2	25	313	1.2	4.4	NA	7.2	909
0	125	28	303	1.2	4.3	5.2	9.2	996
1	117	34	278	1.3	3.9	5.9	7.8	781
2	78.5	32	247	1.1	4.0	4.6	5.7	657
4	37.0	13	197	1.0	3.7	4.0	4.0	510
6	15.1	11	191	0.8	3.6	3.3	4.1	411
8	7.1	8	173	0.9	3.5	2.9	3.7	361
13	2.5	0	112	0.9	3.4	3.0	3.1	305

NA, not available

leukopheresis, hydroxyurea, and/or conventional induction chemotherapy.

This report describes a 74-year-old man with CML myeloid blast crisis who enrolled on an IM trial and developed pulmonary leukostasis while awaiting initiation of therapy. Extensive evaluation for an infectious etiology to the patient's fevers was unrevealing, consistent with a primary diagnosis of pulmonary leukostasis. The patient showed a rapid response to IM with a 38% reduction in his WBC within 36 hours of initiation of therapy and normalization of his WBC by nine days. Peripheral blast counts also decreased rapidly by 30% within 36 hours of initiation of treatment and by 86% after five days on IM therapy. There was no tumor lysis despite the rapid decrease in cell counts. CT scans of the chest revealed diffuse thickening of the intralobular septa with scattered areas of ground glass opacity within the lungs diffusely. Follow-up CT scan showed interval resolution of the intralobular septal thickening and vascular congestion on normalization of the patient's cell counts. A second patient with CML myeloid blast crisis and pulmonary leukostasis treated similarly has also responded rapidly to the addition of IM with resolution of his pulmonary leukostasis.

IM leads to rapid apoptosis of CML cells *in vitro* and rapid lowering of the WBC count in patients with CML.^{8,9} Despite these rapid responses tumor lysis syndrome is rare.^{10,11} This case suggests that IM can be an effective single agent treatment of pulmonary leukostasis in patients with IM-naïve CML myeloid blast crisis. IM may also prove to be an effective agent in combination therapy with traditional treatments such as leukopheresis or hydroxyurea.

Jose F. Leis,¹ Steven L. Primack,² Susan E. Schubach,¹ Peter T. Curtin,¹ Brian J. Druker,¹ Richard T. Maziarz¹

¹Center for Hematologic Malignancies Oregon Health & Science University
Portland, OR 97239-3098,

²Department of Radiology, Oregon Health and Science University Portland,
OR 97239-3098

Correspondence: Jose F. Leis M.D., Ph.D.

Center for Hematologic Malignancies Oregon Health & Science University
Mail code: UHN 73C 3481 S.W. Sam Jackson Park Road
Portland, Oregon 97239-3098

Phone:503-494-1551 Fax:503-494-1552

E-mail:leisj@ohsu.edu

References

- Lester TJ, Johnson JW, Cuttner J. Pulmonary leukostasis as the single worst prognostic factor in patients with acute myelocytic leukemia and hyperleukocytosis. *Am J Med* 1985; 79:43-48.
- Porcu P, Cripe LD, Ng EW, Bhatia S, Danielson CM, Orazi A, et al. Hyperleukocytic leukemias and Leukostasis: A review of pathophysiology, clinical presentation and management. *Leuk Lymph* 2000; 39:1-18.
- Porcu P, Danielson CF, Orazi A, Heerema NA, Gabig TG, McCarthy LJ. Therapeutic leukapheresis in hyperleukocytic leukaemias: lack of correlation between degree of cytoreduction and early mortality rate. *Br J Haematol* 1997; 98:433-436.
- Druker BJ, Sawyers CL, Kantarjian HM, Resta DJ, Reese SF, Ford JM, et al. Activity of a specific inhibitor of the BCR-ABL tyrosine kinase in the blast crisis of chronic myeloid leukemia and acute lymphoblastic leukemia with the Philadelphia chromosome. *N Engl J Med* 2001; 344:1038-1042.
- Kantarjian HM, Cortes J, O'Brien S, Giles FJ, Albitar M, Rios MB. Imatinib mesylate (STI571) therapy for Philadelphia chromosome-positive chronic myelogenous leukemia in blast phase. *Blood* 2002; 99:3547-53.
- Dutcher JP, Schiffer CA, Wiernik PH. Hyperleukocytosis in adult acute nonlymphocytic leukemia: Impact on remission rate and duration, and survival. *J Clin Oncol* 1987; 5:1364-1372.
- Ventura GJ, Hester JP, Smith TL, Keating MJ. Acute myeloblastic leukemia with hyperleukocytosis: Risk factors for early mortality in induction. *Am J Hematol* 1988; 27:34-37.
- Druker BJ, Tamura S, Buchdunger E, Ohno S, Segal GM, Fanning S, et al. Effects of a selective inhibitor of the Abl tyrosine kinase on the growth of Bcr-Abl positive cells. *Nat Med* 1996; 2:561-566.
- Deininger MW, Goldman JM, Lydon N, Melo JV. The tyrosine kinase inhibitor CGP57148B selectively inhibits the growth of BCR-ABL-positive cells. *Blood* 1997; 90:3691-3698.
- Dann EJ, Fineman R, Rowe JM. Tumor lysis syndrome after STI571 in Philadelphia chromosome-positive acute lymphoblastic leukemia. *J Clin Oncol* 2002; 20:354-355.
- Vora A, Bhutani M, Sharma A, Raina V. Severe tumor lysis syndrome during treatment with STI 571 in a patient with chronic myelogenous leukemia accelerated phase. *Annals Oncol* 2002; 13:1833-1834.