



Danazol treatment of idiopathic myelofibrosis with severe anemia

FRANCISCO CERVANTES, JUAN-CARLOS HERNÁNDEZ-BOLUDA, ALBERTO ALVAREZ, ELISABET NADAL, AND EMILIO MONTSERRAT

Institute of Hematology and Oncology, Department of Hematology, IDIBAPS, Hospital Clinic, University of Barcelona, Spain

ABSTRACT

Background and Objectives. Severe anemia is an important problem in patients with idiopathic myelofibrosis (IM). When other therapeutic measures are unsuccessful or not applicable, 40-50% favorable responses are obtained with androgen therapy. Oxymetholone is the drug usually employed, but good results have also been reported with danazol, although the experience is limited to a few patients. The aim of the present study was to evaluate the effect of danazol on the anemia of IM.

Design and Methods. Seven out of 22 consecutive IM patients were eligible for danazol treatment because of severe anemia not treatable with (four cases) or refractory to (three cases) other therapies. Danazol (600-800 mg/day) was given orally for six months and thereafter progressively tapered to the minimum effective dose in responding patients or discontinued in non-responders. Complete response was considered cessation of transfusion requirements with normalization of hemoglobin (Hb) values; partial response was defined as a > 30% reduction in transfusional needs or an increase > 10 g/L in the Hb. The effect on platelet counts was also analyzed.

Results. One patient splenectomized three years earlier achieved a complete response and three a partial response, giving an overall response rate of 57%. A significant increase in platelet counts was also observed in three responders. The responses were first seen between three and six months after the start of treatment, which was usually well tolerated.

Interpretation and Conclusions. Danazol, given at an appropriate dosage for a sufficient time, is an effective treatment for a substantial proportion of IM patients with severe anemia without marked splenomegaly or who have been previously splenectomized.

©2000, Ferrata Storti Foundation

Key words: Idiopathic myelofibrosis, anemia, treatment, androgens, danazol

Correspondence: : Francisco Cervantes, M.D., Hematology Department, Hospital Clinic, Villarroel 170, 08036 Barcelona, Spain.
Phone/Fax: international+34-93-2275475 - E-mail: cervante@medicina.ub.es

Idiopathic myelofibrosis (IM) is an infrequent chronic myeloproliferative disorder characterized by varying degrees of bone marrow fibrosis and extramedullary hematopoiesis, with the fibrosis being a reactive phenomenon to a neoplastic proliferation of a pluripotent hematopoietic stem cell.¹ IM is heterogeneous in presentation and clinical course, with anemia being one of the most important problems. Thus, 20 to 25 % of patients have anemic symptoms at presentation and 50% or more develop severe anemia during the evolution of the disease.^{2,3} The origin of the anemia of IM is multifactorial.² In a proportion of patients with severe anemia without concurrent treatable causes such as iron or folate deficiency, and who are not eligible for either oral chemotherapy, corticosteroids or splenectomy, favorable responses have been reported with androgen therapy.^{1,4-7} Oxymetholone is currently the most used drug,² but good responses have also been reported to danazol, a synthetic attenuated androgen that can also correct thrombocytopenia in some cases.¹ However, the experience with danazol in the treatment of the anemia of IM is limited, with only two reports concerning a total of five patients having been published.^{8,9}

The aim of the present study was to analyze the results of danazol treatment in seven patients with IM in whom anemia was the most important clinical problem.

Design and Methods

Patient eligibility and diagnostic criteria

Among 22 patients consecutively diagnosed with IM at the Hematology Department of the Hospital Clinic of Barcelona between 1995 and 1999, those who had transfusion-dependent anemia or a Hb value below 100 g/L were selected for danazol treatment. Criteria of selection also included lack of criteria for oral chemotherapy, corticosteroids or splenectomy or no response to the latter measures or cyclosporin A, and exclusion of iron, folate or vitamin B12 deficiency and immune hemolytic anemia. The treatment modalities employed in the overall group of 22 IM patients, as well as the characteristics of the subgroup of patients receiving danazol, are summarized in the *Results* section.

The diagnosis of IM was based on the presence of an increased diffuse reticulin and/or collagen bone marrow content with lack of the Ph chromosome or

bcr/abl rearrangement and absence of monocytosis and no apparent cause, with most patients showing the typical picture of palpable splenomegaly, anisopoikilocytosis with tear-drop cells, and leukoerythroblastosis in peripheral blood. Patients with concurrent carcinoma, granulomatous disorders, metabolic osteopathy or lymphoma, as well as those with previous polycythemia vera or essential thrombocythemia, and acute myelofibrosis.¹⁰ Beside this, in those patients without palpable splenomegaly at presentation, special attention was paid to the differential diagnosis with the myelodysplastic syndromes with myelofibrosis, by ruling out the existence of dysplastic features affecting two or more hematopoietic cell lines, characteristic of the latter syndromes, instead of the presence of clusters of abnormal, highly dysplastic megakaryocytes in the bone marrow, characteristic of IM.

Bone marrow histology and cytogenetic study

According to the criteria of Lennert *et al.*,¹¹ three histologic subtypes of IM were considered: MF/C (IM with increased hematopoietic cellularity and reticulin fibrosis), MF/O⁻ (IM with reticulin and collagen fibrosis but no new bone formation), and MF/O⁺ (decreased hematopoietic cellularity, marked reticulin and collagen fibrosis, and osteosclerosis). The karyotype of bone marrow or unstimulated peripheral blood cells was analyzed whenever evaluable metaphases could be obtained.

Treatment schedule, criteria of response and toxicity assessment

Patients were scheduled to receive a six-month course of danazol, 600 to 800 mg (depending on the patient's body weight) per day orally. Following this initial period, in responding patients the drug dosage was decreased to 400 mg/day for an additional six months and then gradually tapered down to the minimum effective dose as maintenance therapy, whereas treatment was discontinued in the non-responders.

A complete response was defined as cessation of transfusion requirements with normalization of the Hb value. The general policy was to transfuse packed

RBC when the Hb levels dropped below 80 g/L or the anemia was overtly symptomatic. A partial response was defined as a $\geq 30\%$ reduction in the number of packed RBC transfused per month as compared to the pre-treatment requirements or an increase ≥ 10 g/L over the baseline Hb levels in patients not previously transfused. The remaining situations were considered as treatment failures.

During the treatment period, in addition to standard hematologic parameters, patients' liver function tests were monitored on a monthly basis and the patients were assessed for the possible development of hepatic tumors by ultrasonography every six months. Adverse effects were also recorded.

Results

Seven out of the 22 patients diagnosed with IM during the study period were considered eligible for danazol treatment. This drug represented the initial therapeutic choice in four cases; two patients received danazol after the anemia failed to respond to corticosteroids or cyclosporin A, and the remaining patients were given danazol therapy after having had spontaneous splenic rupture with subsequent splenectomy three years previously, followed by unsuccessful hydroxyurea treatment. In the remaining 15 patients, the following therapeutic modalities were employed: hydroxyurea (six patients), prednisone (4 cases), splenectomy plus hydroxyurea (one patient), splenectomy plus allogeneic bone marrow transplantation (one case), and wait-and-watch approach (four patients).

Table 1 shows the main characteristics of the seven patients treated with danazol. As can be seen, three of these patients did not have a palpable spleen at disease presentation, whereas one other had been splenectomized. By contrast, out of the 15 patients ascribed to other therapeutic modalities, only two did not have a palpable spleen at IM diagnosis. One patient (#1 in the table) achieved a complete response to danazol and three (#2, 3, and 4) a partial response, whereas the remaining three patients (#5, 6 and 7) failed to respond to therapy. The complete responder was the patient with a history of splenectomy and unsuccessful hydroxyurea treat-

Table 1. Main clinico-hematological characteristics at the start of danazol treatment in seven patients with idiopathic myelofibrosis (IM) and severe anemia.

Patient no.	Age/sex	Spleen size*	Hb (g/L)	Reticulocytes ($\times 10^9/L$)	WBC ($\times 10^9/L$)	Platelets ($\times 10^9/L$)	Histologic phase ^o	Previous treatment [#]	Lapse dx-treatment [#]	Cytogenetics
1	61/M	Splenectomy	62	46	5.1	86	MF/O-	HU	12	Not evaluable
2	55/F	0	73	19	4.3	316	MF/C	CsA	3.5	Der (8)
3	72/M	2	88	47	2.1	14	MF/O-	No	1.5	Not evaluable
4	55/F	8	88	342	7.8	126	MF/O-	No	23	-X, -8, + marker
5	42/M	0	68	12	12.2	103	MF/C	PDN	2	Not evaluable
6	82/F	2	57	81	4.4	220	MF/O-	No	2.5	Del 11 (q23q25)
7	72M	0	70	42	3.8	419	MF/C	No	1.5	Not evaluable

*cm below costal margin; ^oaccording to Lennert *et al* (1975); [#]HU: hydroxyurea, CsA: cyclosporin A, PDN: prednisone; [#]in months

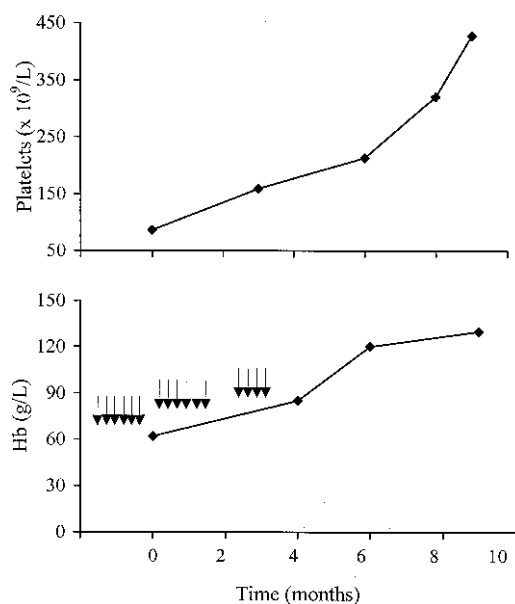


Figure 1. Complete response to danazol treatment in a IM patient with transfusion-dependent anemia and thrombocytopenia. Every packed RBC transfusion is represented by an arrow.

ment. As depicted in Figure 1, his transfusional needs decreased from the third month of treatment, his Hb values normalized and he became transfusion-independent from the sixth month after starting treatment. This situation persists at 10 months after the start of danazol treatment. In one of the three partial responders the monthly transfusion requirements decreased from 6 to 3 and 2 packed RBC units at six and eight months, respectively, whereas in another patient they decreased from 5 to 2 transfused packed RBC units per month at six months. The third partial responder (patient #4 in the table) had never been transfused before the start of treatment, and showed an increase in the Hb values from 88 to 98 g/L at four months of therapy. At that time, she decided to discontinue the drug because of persistent and treatment-attributed headache, and this was followed by a progressive decrease in her Hb levels, which increased again once danazol was recommenced. Overall, in the above four patients the first signs indicating a possible response to danazol were noted between three and six months after the start of treatment.

Among the three non-responders, one patient died from pneumonia without showing signs of hematological response, three and a half months after the start of danazol therapy, which had been instituted after the failure of prednisone treatment. In another patient IM evolved into acute myeloblastic leukemia one year after diagnosis, whereas the third non-

responder showed no change in his transfusional needs after six months of treatment.

After six months of therapy, three of the responding patients showed significant increases in their platelet counts: from 86 to $213 \times 10^9/L$ (patient #1), from 14 to $26 \times 10^9/L$ (patient #3), and from 316 to $515 \times 10^9/L$ (patient #2).

Except for the patient who complained of persistent headache coincidentally with danazol administration, treatment was clinically well tolerated. A moderate increase in the serum transaminase levels (< 200 IU/L) was observed in two patients. No case of peliosis hepatis or liver cell adenoma was registered during the study period.

Discussion

Idiopathic myelofibrosis, the least frequent of the chronic myeloproliferative disorders, is markedly variable in its clinicohematologic presentation and evolution.^{12,13} From the clinical point of view, anemia is an important problem in a majority of IM patients; indeed 50% or more of them have severe anemia at diagnosis or during the evolution of the disease.^{2,3} Moreover, the degree of anemia has been found to be the most important prognostic factor of IM.¹⁴⁻¹⁸ Except for the minority of younger patients in whom allogeneic marrow transplantation can be carried out,¹⁹ no curative therapy is currently available for IM. Because of this, and given the multifactorial origin of the anemia in IM, treatment decisions should take into account the main mechanisms operating in each individual patient. In this sense, ineffective hematopoiesis, splenic red cell sequestration, hemodilution due to plasma volume expansion secondary to splenomegaly, and hemolysis are the major mechanisms contributing to the anemia, whereas iron and particularly folate or vitamin B12 deficiency are less often observed.² In IM patients with severe anemia in whom the latter three causes have been excluded and who are not eligible for other therapeutic measures such as oral chemotherapy, corticosteroids or splenectomy, a trial with androgen therapy is indicated.

The efficacy of androgen therapy in the anemia of IM has been well recognized since the pioneering reports by Kennedy⁴ and Silver *et al.*⁵ The main mechanism of action of the androgens in these patients seems to be stimulation of bone marrow function.² Currently, oxymetholone is the drug most widely used, producing favorable responses in approximately 40-50% of cases.^{2,7} Good results have also been reported with danazol, a synthetic, attenuated drug that has proved to be useful in some patients with hematologic disorders such as idiopathic thrombocytopenic purpura,²⁰ autoimmune hemolytic anemia²¹ and myelodysplastic syndromes.²² As far as IM is concerned, the experience with danazol treatment is very limited, since only two such reports are available in the medical literature. Chabannon *et al.*⁸ reported the case of a patient with IM who experienced a transient improvement in his severe anemia and thrombocytopenia coincidentally with the administration of danazol. More recently, Lévy *et al.*⁹ reported on four patients with IM and severe ane-

mia, two of whom had a complete response to danazol treatment and the other two a partial response. Correction of thrombocytopenia was observed in one of the four patients and disappearance of the splenomegaly in two. No side effect was registered. However, given the character of case reports of the above two studies, it is not possible to infer the criteria used for the selection of patients for danazol treatment.

In the present series, one third of the patients diagnosed with IM in a single institution during a four-year period were eligible for danazol therapy. The fact that three of the seven patients assigned to this treatment did not have palpable splenomegaly (one of them because of previous splenectomy) clearly reflects a selection bias in the danazol group, i. e., that patients with marked splenomegaly were usually assigned to other therapeutic modalities. In this sense, it must be pointed out that in those patients with bone marrow biopsy and peripheral blood features typical of IM but without a palpable spleen, special attention was given to establishing the differential diagnosis from the myelodysplastic syndromes with myelofibrosis. In fact, although universally accepted diagnostic criteria for IM do not exist, our patients fulfilled the criteria recently proposed by the Italian Consensus Conference for the diagnosis of the disease.²³

The 55 % favorable responses obtained with danazol treatment in our patients, with a complete response being observed in one of them, confirms the effectiveness of this drug in the anemia of IM and compares favorably with the 40-50% usually obtained with oxymetholone.^{2,7} Additional advantages of danazol would be the correction of the thrombocytopenia observed in most responders and the limited toxicity associated with the treatment. From a practical point of view, the fact that in responding patients the first signs of the favorable response were noted between the third and sixth month of treatment is especially noteworthy. This observation reinforces the notion that danazol treatment must not only be given at an appropriate dosage but also for a minimum period of six months before treatment can be considered to have failed. The mechanism of action of danazol is not well known. It has been speculated that, in addition to its marrow-stimulating activity, and similarly to its hypothetical effect in the myelodysplastic syndromes,²² it improves cytopenias by decreasing the number of monocyte Fcγ receptors.

The small number of patients treated with danazol in the present series precludes comparison of the characteristics of the responders and non-responders. However, a roughly similar distribution of patients was observed in the two subgroups in terms of splenomegaly and presence of karyotypic abnormalities. This is of note, since the better responses to androgen therapy have been reported to occur in IM patients previously splenectomized or lacking massive splenomegaly and in those with a normal karyotype.^{2,6}

Based on the results herein reported, as well as on previous similar observations, we conclude that danazol, given at an appropriate dosage and for a minimum of six months, can be useful in a propor-

tion of patients with IM and severe anemia. In any case, taking into account the lack of an effective therapy for the majority of patients with IM, further studies are required aimed at evaluating the possible role in this disease of newer treatment strategies, for instance, the use of anti-angiogenic drugs.²⁴

Potential implications for clinical practice

- ◆ Danazol, given at a dose of 600 to 800 mg/day, can be an effective treatment for IM patients with severe anemia in whom other treatable causes have been excluded.
- ◆ The drug must be given for a minimum period of 6 months before the treatment can be considered to have failed, since the favorable responses are usually seen between three and six months after the start of treatment.

Contributions and Acknowledgments

FC was responsible for clinical assessment of the patients, conception and design of the study and writing of the paper. JC-HB, AA and EN helped in study design, data collection, follow-up updating and production of the figure and table. EM helped in writing the paper. The order in which the names of the authors appear is based on the importance of their contributions, with EM being the head of the Hematology Department.

Disclosures

Conflict of interest: none.

Redundant publications: no overlapping with previous papers.

Manuscript processing

Manuscript received December 23, 1999; accepted March 16, 2000.

References

1. Jacobson RJ, Salo A, Fialkow PJ. Agnogenic myeloid metaplasia: a clonal proliferation of hematopoietic stem cells with secondary myelofibrosis. *Blood* 1978; 51:189-94.
2. Reilly JT. Pathogenesis and management of idiopathic myelofibrosis. *Baillier Clin Haem* 1998; 751-77.
3. Centenara E, Guarnone R, Ippoliti G, Barosi G. Cyclosporin-A in severe refractory anemia of myelofibrosis with myeloid metaplasia: a preliminary report. *Haematologica* 1998; 83:622-6.
4. Kennedy BJ. Effect of androgenic hormone in myelofibrosis. *JAMA* 1962; 182:114-9.
5. Silver RT, Jenkins DE Jr, Engle RL. Use of testosterone and busulfan in the treatment of myelofibrosis with myeloid metaplasia. *Blood* 1964; 23:341-53.
6. Besa EC, Nowell PC, Geller NL, Gardner FH. Analysis of the androgen response of 23 patients with agnogenic myeloid metaplasia: the value of chromosomal studies in predicting response and survival. *Cancer* 1982; 49:308-13.
7. Hast R, Engstedt L, Jameson S, et al. Oxymetholone treatment in myelofibrosis. *Blut* 1978; 37:19-26.
8. Chabannon C, Pegourie B, Sotto JJ, Hollard D. Clinical and hematological improvement in a patient receiving danazol therapy for myelofibrosis with myeloid metaplasia. *Nouv Rev Fr Hematol* 1990;

- 32:165-6.
9. Levy V, Bourgarit A, Delmer A, et al. Treatment of agnogenic myeloid metaplasia with danazol: a report of four cases. *Am J Hematol* 1996; 53:239-41.
 10. Cervantes F, Pereira A, Esteve J, et al. Identification of "short-lived" and "long-lived" patients at presentation of idiopathic myelofibrosis. *Br J Haematol* 1997; 97:635-40.
 11. Lennert K, Naghai K, Schwarze EW. Patho-anatomical features of the bone marrow. *Clin Haematol* 1975; 4:331-51.
 12. Hasselbach H. Idiopathic myelofibrosis: a clinical study of 80 patients. *Am J Hematol* 1990; 4:291-300.
 13. Cervantes F, Pereira A, Esteve J, Cobo F, Rozman C, Montserrat E. The changing profile of idiopathic myelofibrosis: a comparison of the presenting features of patients diagnosed in two different decades. *Eur J Haematol* 1998; 58:101-5.
 14. Njoku OS, Lewis SM, Catovsky D, Gordon-Smith EC. Anaemia in myelofibrosis: its value in prognosis. *Br J Haematol* 1983; 54:79-89.
 15. Barosi G, Berzuini C, Liberato LN, Costa A, Polino G, Ascari E. A prognostic classification of myelofibrosis with myeloid metaplasia. *Br J Haematol* 1988; 70:397-401.
 16. Visani G, Finelli C, Castelli U, et al. Myelofibrosis with myeloid metaplasia: clinical and haematological parameters predicting survival in a series of 133 patients. *Br J Haematol* 1990; 75:4-9.
 17. Dupriez B, Morel P, Demory JL, et al. Prognostic factors in agnogenic myeloid metaplasia: a report on 195 cases with a new scoring system. *Blood* 1996; 88:1013-8.
 18. Cervantes F, Barosi G, Demory JL, et al. Myelofibrosis with myeloid metaplasia in young individuals: disease characteristics, prognostic factors and identification of risk groups. *Br J Haematol* 1998; 102:684-90.
 19. Guardiola P, Anderson JE, Bandini G, et al. Allogeneic stem cell transplantation for agnogenic myeloid metaplasia: A European Group for Blood and Marrow Transplantation, Société Française de Greffe de Moelle, Gruppo Italiano per il Trapianto del Midollo Osseo, and Fred Hutchinson Cancer Research Center Collaborative Study. *Blood* 1999; 93:2831-8.
 20. Ahn YS, Harrington WJ, Simon SR, Mylvaganam R, Pall LM, So AG. Danazol for the treatment of idiopathic thrombocytopenic purpura. *N Engl J Med* 1983; 308:1396-9.
 21. Ahn YS, Harrington WJ, Mylvaganam M, Ayub J, Pall LM. Danazol therapy for autoimmune hemolytic anemia. *Ann Intern Med* 1985; 102:298-301.
 22. Stadtmauer EA, Cassileth PA, Edelstein M, et al. Danazol treatment of myelodysplastic syndromes. *Br J Haematol* 1991; 77:502-8.
 23. Barosi G, Ambrosetti A, Finelli C, et al. The Italian Consensus Conference on Diagnostic Criteria for Myelofibrosis with Myeloid Metaplasia. *Br J Haematol* 1999; 104:730-7.
 24. Thomas DA, Aguayo A, Giles FJ, et al. Thalidomide anti-angiogenesis therapy in Philadelphia-negative myeloproliferative disorders and myelofibrosis. *Blood* 1999; 10(Suppl 1):702a.