

3. Schattner E, Bussel J. Mortality in immune thrombocytopenic purpura: report of seven cases and consideration of prognostic indicators. *Am J Hematol* 1994; 46:120-6.
4. Adams DB, Zellner JL, Anderson MC. Arterial hemorrhage complicating pancreatic pseudocysts: role of angiography. *J Surg Res* 1993; 54:150-6.
5. Fallon FG, Wilson WH, Thomford NR. Gastroepiploic arteriovenous fistula. A complication of splenectomy. *Ohio State Med J* 1969; 65:45-9.
6. Sugg SL, Gerndt SJ, Hamilton BJ, et al. Pseudoaneurysms of the intraparenchymal splenic artery after blunt abdominal trauma: a complication of non-operative therapy and its management. *J Trauma* 1995; 39:593-5.
7. Nance FC, Nance ML. Delayed presentation of splenic artery pseudoaneurysms following blunt abdominal trauma. *J Trauma* 1995; 39:620-1.

### Leukemoid reaction preceding the diagnosis of colorectal carcinoma by four years

Sir,

We report the case of a patient in whom neutrophilic leukocytosis was discovered incidentally. He had no signs suggesting infection or neoplasia, and the results of the hematologic study were consistent with chronic neutrophilic leukemia. He remained asymptomatic for four years, with his leukocyte counts ranging from  $12.9$  to  $40 \times 10^9/L$ , until he developed intestinal obstruction that led to the discovery of a colorectal carcinoma. The diagnosis of leukemoid reaction was finally established after surgical resection of the tumor was followed by normalization of the leukocyte count.

Chronic neutrophilic leukemia (CNL) is an exceedingly infrequent myeloproliferative disorder in which most of the circulating myeloid cells are mature granulocytes.<sup>1,2</sup> Differential diagnoses of CNL include, among others, leukemoid reaction to malignant neoplasias. In clinical practice, tumors producing leukemoid reaction characteristically have an aggressive clinical course and, because of this, both diagnoses are usually established either simultaneously or closely in time. We report the case of a patient with neutrophilic leukocytosis that preceded by four years the diagnosis of colorectal carcinoma.

A 78-year old man was referred to our center in November 1994 due to the incidental discovery of neutrophilic leukocytosis a few months earlier. The patient was asymptomatic, did not report visible blood loss in the stools or alterations in his bowel habits, and his physical examination was normal. Main laboratory data were: Hb 15.4 g/dL, WBC count  $16.7 \times 10^9/L$  (neutrophils 84%, lymphocytes 10%, monocytes 6%), platelet count  $106 \times 10^9/L$ , ESR 6 mm/h, serum LDH level 470 IU/L (normal value: 250-450 IU/L), and uric acid 8.4 mg/dL. Serum cobalamin level and vitamin B12 binding capacity were increased, and the leukocyte alkaline phos-

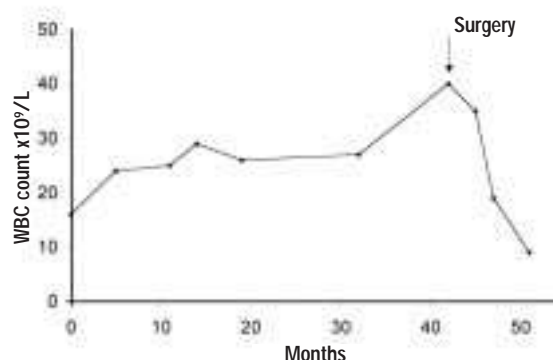


Figure 1. Evolution of the patient's leukocyte counts from first observation to latest follow-up.

phatase (LAP) score was also high. A bone marrow aspirate displayed increased cellularity with myeloid hyperplasia, and similar findings were seen in the marrow biopsy, with no fibrosis. Bone marrow cytogenetic study was normal and rearrangement of the *bcr/abl* gene was not observed. Since there were no signs suggesting infection or neoplasia, a tentative diagnosis of chronic neutrophilic leukemia (CNL) was established but, due to the moderate leukocytosis, no treatment was instituted. During the ensuing three and a half years, the patient remained asymptomatic, with his leukocyte counts ranging from  $12.9$  to  $40 \times 10^9/L$ . Most of the leukocytes were mature neutrophils. In June 1998 he suddenly developed intestinal obstruction, which led to a diagnosis of colorectal carcinoma. Surgical resection of the carcinoma was followed by rapid normalization of the WBC counts, which have remained normal throughout the subsequent follow-up (Figure 1).

Persistent leukocytosis in the absence of infection in patients with malignant neoplasias is known as leukemoid reaction. The exact mechanisms underlying this phenomenon are not well established. Recent reports on solid tumors associated with neutrophilic leukocytosis suggest that cytokine production by the tumor increases granulocyte production, therefore resulting in the leukemoid reaction. Indeed, the production of granulocyte colony-stimulating factor (G-CSF), granulocyte-macrophage-CSF, interleukin-1, and/or interleukin-6 by bladder,<sup>3,4</sup> lung<sup>5</sup> and tongue<sup>6</sup> carcinomas has been described in association with leukemoid reactions. However, the fact that no detectable cytokines can be found in other patients indicates that neutrophilic leukocytosis may be induced by mechanisms other than the above described.<sup>7</sup> From the clinical point of view, the presence of a leukemoid reaction in the setting of a malignant tumor usually reflects an aggressive clinical

course of the latter. In this context, the present case would represent an exceedingly rare instance of leukemoid reaction, since the neutrophilic leukocytosis was incidentally discovered in an otherwise asymptomatic patient four years prior to the diagnosis of a colorectal carcinoma. Based on the present observation we conclude that the diagnosis of leukemoid reaction must be taken into account whenever persistent neutrophilic leukocytosis is observed, even in asymptomatic patients with no clinical signs of infection or neoplasia. In such cases a search for occult neoplasia is, therefore, mandatory.

Ana Ferrer, Francisco Cervantes, Juan-Carlos Hernández-Boluda,  
Alberto Alvarez, Emilio Montserrat

Hematology Department, Hospital Clinic, Institut d'Investigacions  
Biomèdiques (IDIBAPS), University of Barcelona, Spain

### Key words

Leukemoid reaction, chronic neutrophilic leukemia, colorectal carcinoma

### Correspondence

Ana Ferrer, MD, Hematology Department, Hospital  
Clínic, Villarroel 170, 08036 Barcelona, Spain.

Phone&Fax: international +34-93-2275428.

### References

1. Zittoun R, Réa D, Hoang Ngoc L, et al. Chronic neutrophilic leukemia. A study of four cases. *Ann Hematol* 1994; 68:55-60.
2. Rovira M, Cervantes F, Nomdedeu B, et al. Chronic neutrophilic leukemia preceding for seven years the development of multiple myeloma. *Acta Haematol* 1990; 83:94-5.
3. Sato K, Terada K, Sugiyama T, et al. Granulocyte colony-stimulating factor produced by bladder carcinoma of a patient with leukemoid reaction did not affect proliferation of the tumor cells. *J Urol* 1994; 151:1687-90.
4. Miller J, Sarver RG, Drach GW. Leukemoid reaction: a rare paraneoplastic syndrome associated with advanced bladder carcinoma. *Urology* 1994; 44:444-6.
5. Watanabe M, Ono K, Ozaki Y, et al. Production of granulocyte-macrophage colony-stimulating factor in a patient with metastatic chest wall large cell carcinoma. *Jpn J Clin Oncol* 1998; 28:559-62.
6. Horii A, Shimamura K, Honjo Y, et al. Granulocyte colony-stimulating factor-producing tongue carcinoma. *Head & Neck* 1997; 19:351-6.
7. Saussez S, Heimann P, Vandeveld L, et al. Undifferentiated carcinoma of the nasopharynx and leukemoid reaction: report of case with literature review. *J Laryngol Otol* 1997; 111:66-9.