TAFRO-like syndrome associated with long-term CAR T-cell persistence after axicabtagene ciloleucel therapy

Chimeric antigen receptor (CAR) T-cell therapy has substantially improved outcomes in relapsed or refractory B-cell malignancies. While early toxicities such as cytokine release syndrome (CRS), immune effector cell-associated neurotoxicity syndrome (ICANS), and immune effector cell-associated hematotoxicity (ICAHT) are well characterized,[1] delayed immune-mediated complications may also arise and remain incompletely understood. TAFRO (thrombocytopenia, anasarca, fever, reticulin myelofibrosis and organomegaly) syndrome is a rare, aggressive systemic inflammatory disorder described by Takai *et al.*[2] in 2010, which is currently considered a clinical subtype of idiopathic multicentric Castleman disease (iMCD) characterized by dysregulated activation of multiple inflammatory pathways.[3]

Here, we describe a previously unreported case of a TAFRO-like syndrome occurring as a delayed event temporally associated with axicabtagene ciloleucel (axi-cel) CAR T-cell therapy.

A 72-year-old man was diagnosed in January 2009 with stage 2B T-cell/histiocyte-rich large B-cell lymphoma EBER-negative and achieved complete remission after R-CHOP. He relapsed in November 2009 and achieved a second complete remission after R-ESHAP and autologous transplantation. In September 2021, a second relapse with bone marrow (BM) involvement was diagnosed as Epstein-Barr virus (EBV)-positive diffuse large B-cell lymphoma (DLBCL), treated with R-ICE. A third relapse occurred in June 2023, again EBV-positive with BM involvement. He received R-GEMOX bridging followed by axi-cel CAR T-cell therapy in November 2024. The patient provided written informed consent for the use of anonymized clinical data in research, in accordance with the ethical standards and regulations in Spain.

At the time of CAR T-cell therapy, the patient was in complete remission without BM involvement and undetectable EBV DNAemia by quantitative polymerase chain reaction (qPCR). The baseline CAR-HEMATOTOX score was 2, denoting high-risk status for severe and prolonged hematotoxicity and indicating limited pre-existing marrow reserve. The immediate post-infusion course was uncom-

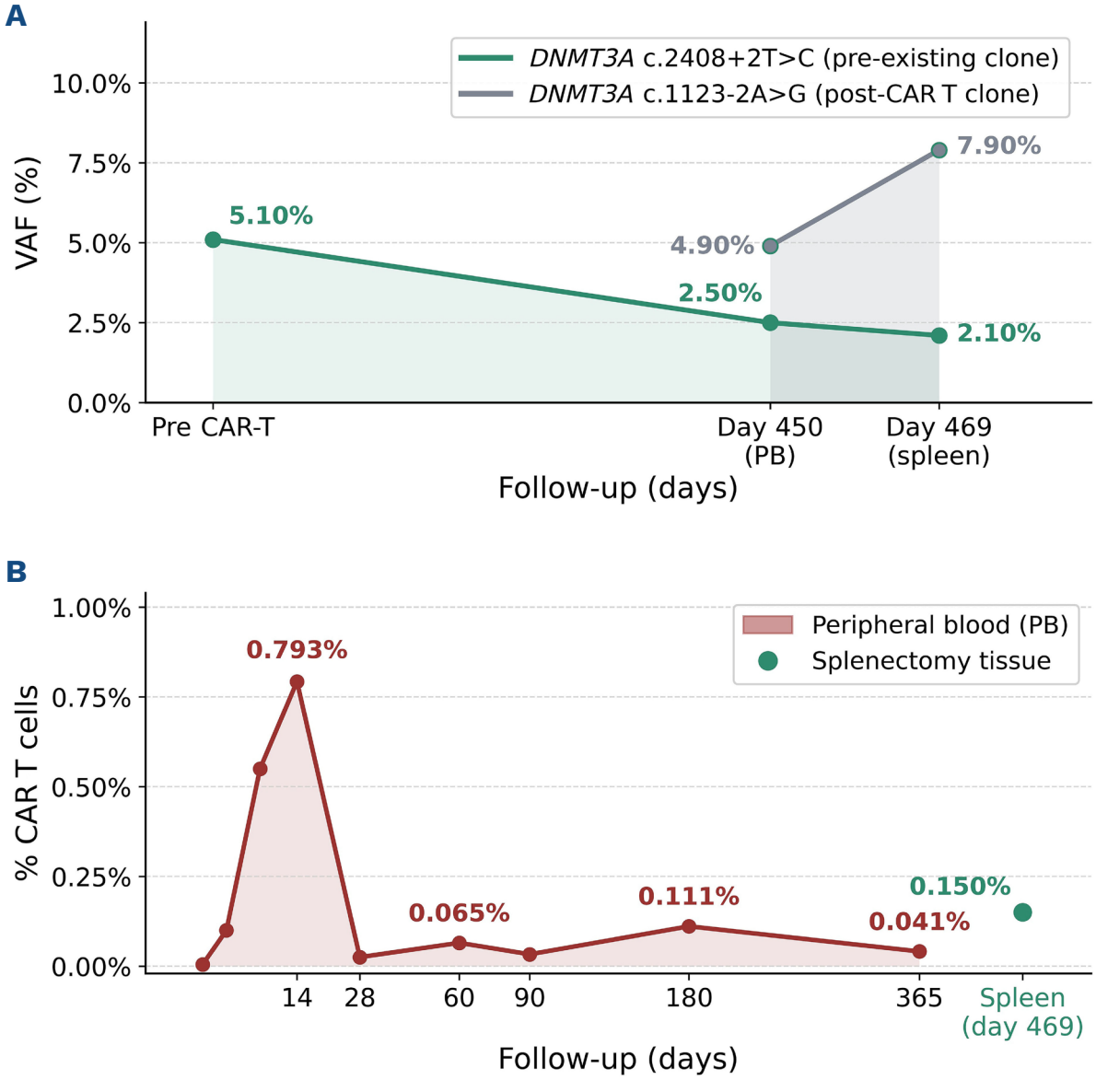

Figure 1. Molecular evolution of TAFRO-like syndrome after CAR T therapy. (A) Longitudinal analysis of clonal hematopoiesis dynamics. A pre-existing *DNMT3A*-mutated clone (c.2408+2T>C, green) was detected before chimeric antigen receptor T (CAR T) cell infusion (variant allele frequency [VAF] 5.10%) and declined thereafter (2.50% in peripheral blood [PB] at day 450 and 2.10% in splenectomy tissue at day 469). A second variant (c.1123-2A>G, grey) emerged after infusion, with reversed VAF in PB (4.90%) *versus* splenectomy tissue (7.90%), supporting tissue-specific clonal dynamics. (B) CAR T-cell kinetics by digital polymerase chain reaction. Expansion peaked at day 14 (0.793%) in PB and contracted progressively. Persistent CAR T cells were detected at day 365 in PB (0.041%) and in splenectomy tissue at day 469 (0.150%), confirming long-term *in vivo* CAR T-cell persistence. TAFRO: thrombocytopenia, anasarca, fever, reticulin myelofibrosis and organomegaly.

plicated, without infections, CRS or ICANS. Hematological recovery was documented (platelets ≥100×10^9/L at day +10, neutrophils ≥2.5×10^9/L at day +59), although hemoglobin never exceeded 11.7 g/dL; thereafter, all three lineages progressively declined.

Three months after infusion (March 2025), positron emission tomography-computed tomography (PET-CT) demonstrated diffusely increased BM metabolic activity without focal lesions suggestive of lymphoma relapse. BM biopsy performed showed hypocellular marrow (20% cellularity) with regenerative features and no evidence of lymphoma. In August 2025, persistent cytopenias and concern for a therapy-related myeloid neoplasm prompted a BM aspirate. Non-significant myeloid dysplasia affecting fewer than 10% of cells was observed, with no increase in blasts. Next-generation sequencing analysis of the pre-CAR T BM biopsy identified a subclonal *DNMT3A* mutation (c.2408+2T>C; variant allele frequency [VAF] 5.10%). These findings - cytopenias, non-significant dysplasia, and a subclonal *DNMT3A* variant - were consistent with clonal cytopenia of undetermined significance (CCUS).

In October 2025, a trephine BM biopsy showed hypercellular marrow (40-50%) with preserved trilineage hematopoiesis and grade 3 reticulin fibrosis. Megakaryocytes were increased but normal, without atypia, blasts, or lymphoma infiltration. In February 2026, the patient developed severe pancytopenia associated with marked systemic inflammation, including C-reactive protein (CRP) 102.2 mg/L, ferritin 2,863 ng/mL, interleukin 6 (IL-6) 23.40 pg/mL, and acute renal failure with creatinine 2.76 mg/dL, whereas renal function had previously been normal. Triglycerides and fibrinogen were within normal limits (98 mg/dL and 3.06 g/L, respectively). PET-CT demonstrated splenomegaly (16 cm, maximum standardized uptake value [SUV$_{max}$] 7), bilateral pleural effusion, ascites, and diffuse BM hypermetabolism without lymphadenopathy. Microbiological and cytological analyses were negative. A new BM biopsy revealed markedly hypercellular marrow (80% cellularity) with extensive reticulin fibrosis and diffuse/nodular interstitial infiltration by small CD3-positive T lymphocytes. These cells preserved expression of pan-T-cell markers (CD2, CD5, CD7), with slight CD8 predominance and no cytologic atypia. T-cell receptor (TCR) gene rearrangement studies by molecular biology demonstrated a polyclonal pattern, excluding a clonal T-cell process. No abnormal B-cell population, including no detectable CD19-positive B cells, was identified in the BM at this or any prior timepoint; EBER was negative. Megakaryocytes were distributed interstitially and preserved normal morphology. No increase in blasts or hemophagocytosis was observed.

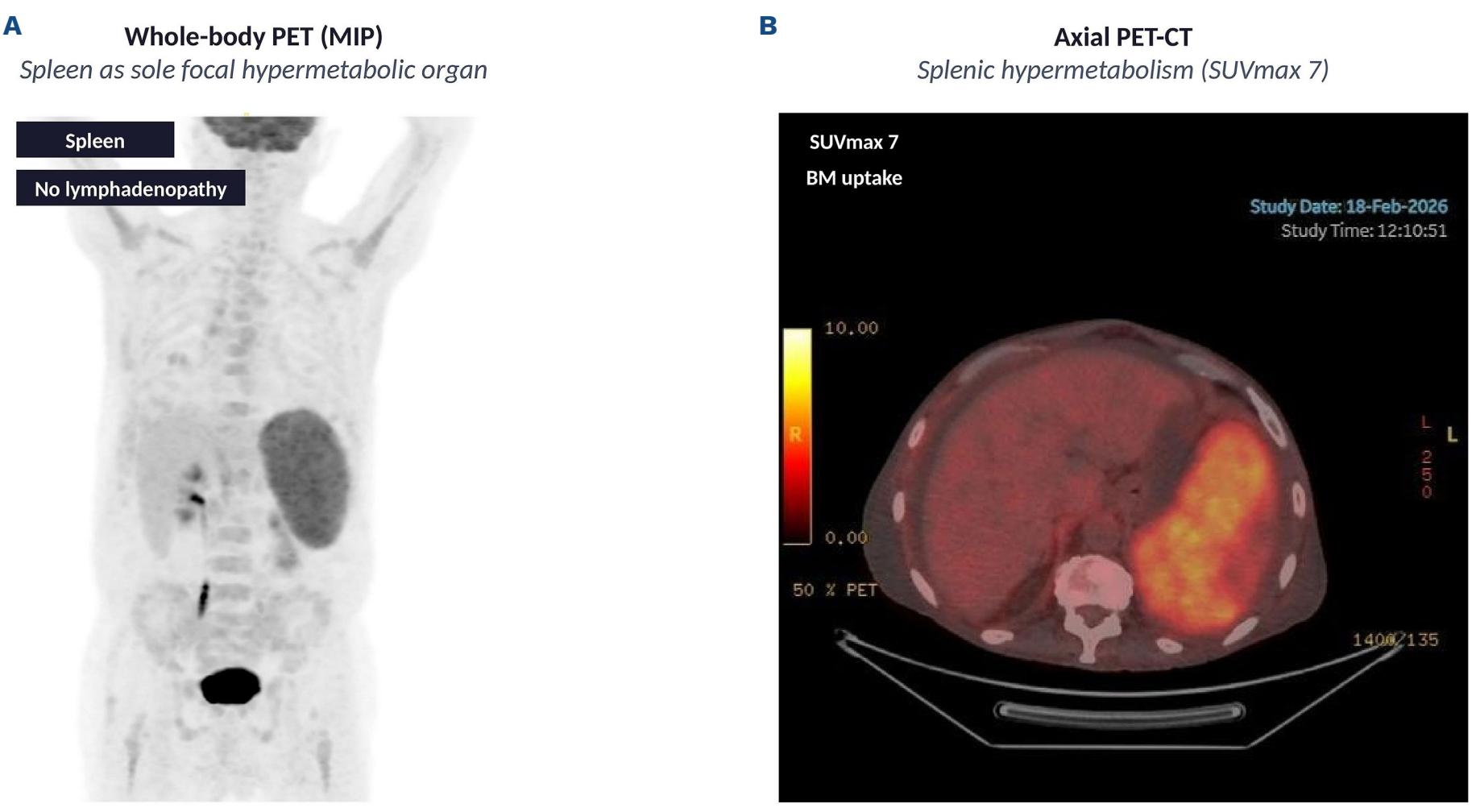

Figure 2. Positron emission tomography-computed tomography findings in February 2026. (A) Whole-body positron emission chromatography (PET). The spleen is the sole focally hypermetabolic organ, with no hypermetabolic lymphadenopathy above or below the diaphragm. (B) Axial fused PET-computed tomography (PET-CT). Marked splenic hypermetabolism (maximum standardized uptake value [SUV$_{max}$] 7) with splenomegaly (16 cm) and diffuse bone marrow hypermetabolism. Subcapsular hypodense ametabolic splenic lesions are consistent with splenic infarcts. BM: bone marrow.

As lymphoma was excluded on BM biopsy and the spleen represented the sole focally hypermetabolic organ on PET-CT (Figure 2), splenectomy was performed in March 2026. Pathology showed diffuse micronodular fibrosis replacing the splenic parenchyma with a T-cell-predominant infiltrate, without extramedullary hematopoiesis or lymphomatous involvement. Sequential histopathological findings involving BM and spleen are summarized in Figure 3.

Post-CAR T molecular studies showed no mutations in *JAK2, CALR*, or *MPL* genes. However, reassessment of *DNMT3A*-mutated hematopoiesis demonstrated persistence and clonal evolution. In peripheral blood (PB), two *DNMT3A* variants were identified: c.1123-2A>G (VAF 4.9%) and c.2408+2T>C (VAF 2.5%). The same variants were detected in splenectomy tissue, but with reversed proportions (2.1% and 7.9%, respectively), supporting tissue-specific clonal dynamics after CAR T-cell therapy (Figure 1A). T-cell receptor studies demonstrated a polyclonal pattern; however, dPCR detected persistent CAR T cells in splenic tissue (0.15%) and PB (0.041%) 1-year post-infusion (Figure 1B). Comprehensive microbiological studies (Cytomegalovirus, EBV, mycobacteria, and others) were repeatedly negative.

Overall, the findings fulfilled the updated 2019 Masaki diagnostic criteria for TAFRO syndrome, in the context of persistent CAR T cells and immune activation.[4] The patient met all three major criteria - thrombocytopenia, systemic inflammation (fever and CRP of 102.2 mg/L), and anasarca - together with reticulin myelofibrosis, splenomegaly, and acute renal dysfunction. The differential diagnosis included primary myelofibrosis (excluded by the absence of *JAK2/CALR/MPL* mutations and of megakaryocytic atypia), hemophagocytic lymphohistiocytosis (HLH), autoimmune myelofibrosis (excluded by absence of autoantibodies or systemic autoimmune disease),[5] and T-cell lymphoma (excluded by polyclonal TCR rearrangement). HLH was considered unlikely: four of eight assessed HLH-2004 criteria were met - fever, splenomegaly, pancytopenia, and elevated ferritin - whereas triglycerides and fibrinogen were normal and no hemophagocytosis was identified on BM or splenic histopathology[6] (H-score 110, consistent with a low probability of HLH).

The two *DNMT3A* splice-site variants, with subclonal VAF and tissue-specific dynamics, were most consistent with age-related clonal hematopoiesis. This interpretation remains hypothesis-generating, but we propose that these variants acted as inflammatory amplifiers rather than mere bystanders. *DNMT3A*-mutant hematopoietic progenitors secrete IL-6 and tumor necrosis factor α (TNFα), induce stromal senescence, and amplify inflammation via paracrine activation of wild-type cells.[7] Conversely, the resulting pro-inflammatory milieu selectively enhances the fitness of *DNMT3A*-mutated clones,[8] creating a bidirectional feedback loop between clonal expansion and cytokine production. In this case, the persistent CAR T-associated inflammatory milieu may have favored clonal dominance, while the expanding *DNMT3A*-mutated compartment amplified cytokine output. Clonal evolution of *DNMT3A*-mutated hematopoiesis after CAR T-cell therapy, and its association with hematologic toxicity and secondary myeloid events, has been reported, although in our case VAF remained subclonal throughout

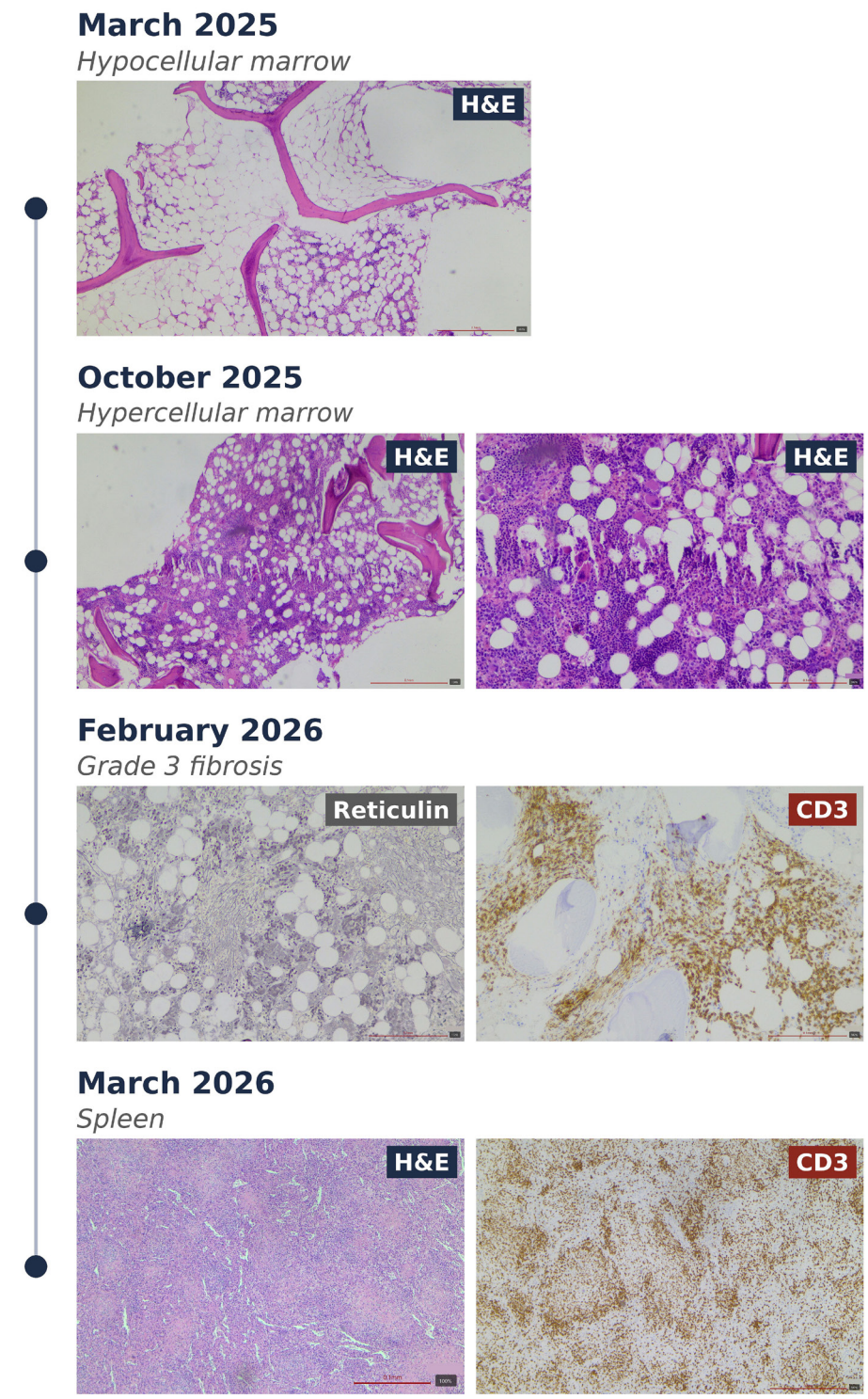

Figure 3. Histopathological timeline of post-CAR T-cell systemic fibro-inflammatory syndrome. Sequential bone marrow (BM) and splenic histopathological changes following axicabtagene ciloleucel infusion. March 2025: hypocellular bone marrow (BM, 20% cellularity) with regenerative features (hematoxylin-eosin stain [H&E]). October 2025: hypercellular BM (panoramic view, left) with a higher-magnification field showing morphologically normal megakaryocytes (right) (H&E). February 2026: grade 3 reticulin fibrosis (reticulin stain) with a diffuse interstitial CD3-positive T-cell infiltrate (CD3 immunostaining). March 2026 (splenectomy): diffuse micronodular fibrosis replacing splenic parenchyma (H&E) with predominant CD3$^+$ T-cell infiltrate (CD3 immunostaining); no extramedullary hematopoiesis or lymphoma. These findings support a progressive fibro-inflammatory process driven by persistent immune activation. Scale bars=0.1 mm. CAR T: chimeric antigen receptor T cell.

follow-up, with no dysplastic or blast evolution, arguing against transformative potential.[9,10]

Yeung *et al.*[11] previously described post-CAR T BM abnormalities (hypocellularity, reactive infiltrates, reticulin fibrosis - the latter associated with inferior survival) largely confined to the BM compartment. The systemic fibro-inflammatory picture observed in the present case, with extensive splenic fibrosis and serositis, expands the known spectrum of CAR T-related toxicities and prompted investigation into a unifying pathogenic mechanism. This pathogenic framework is biologically plausible given that TAFRO syndrome is characterized by several dysregulated cytokine signaling pathways involving IL-6, TNFα, VEGF, and the JAK-STAT and NF-κB pathways. IL-6–mediated JAK1 activation and NF-κB-driven IL-6/VEGF transcription generate a self-amplifying inflammatory loop with endothelial activation and progressive tissue injury.[3]

Conventional iMCD-TAFRO treatment relies on corticosteroids followed by anti-IL-6 therapy (tocilizumab, siltuximab).[12] However, this targets a single cytokine, whereas CAR T-associated dysregulation involves multiple pro-inflammatory signals converging on the JAK-STAT pathway. Importantly, tocilizumab does not suppress CAR T expansion or persistence and, by blocking IL-6 receptor signaling, paradoxically raises circulating IL-6 while leaving other pro-inflammatory axes unaddressed.[13] In contrast, ruxolitinib, a JAK1/2 inhibitor, acts downstream of multiple cytokine receptors simultaneously, dampening the self-amplifying inflammatory loop regardless of its upstream origin.[14] Additionally, JAK-STAT inhibition with ruxolitinib has demonstrated protective effects on endothelial activation, potentially mitigating the vascular injury component of the inflammatory loop.[15]

Treatment was initiated with methylprednisolone 40 mg daily for 5 days (March 12-16, 2026), followed by ruxolitinib 10 mg twice daily from March 17. CRP decreased markedly from 109.1 mg/L on March 11 to 16.7 mg/L by March 20, and remained substantially below baseline values (generally 20-40 mg/L) over the subsequent weeks under ruxolitinib. Renal function had recovered before treatment initiation (March 5). Pleural effusion and ascites resolved by April 10, with no subsequent recurrence of anasarca. Cytopenias improved only partially, with platelet counts stabilizing in the 30-55×10^9/L range, persistent anemia (hemoglobin 8-9 g/dL), and moderate neutropenia (ANC 0.6-1.0×10^9/L), likely reflecting residual BM niche dysfunction.

After 11 weeks of follow-up from ruxolitinib initiation, the patient died on June 2, 2026, from probable invasive pulmonary aspergillosis (*Aspergillus fumigatus* detected by PCR on bronchoalveolar lavage, with compatible radiological findings) together with concurrent respiratory syncytial virus infection. This fatal infectious outcome was likely multifactorial, reflecting the cumulative immunosuppressive burden of extensive prior treatment, CAR T persistence, prolonged hematotoxicity, splenectomy, and JAK inhibition - a convergence of factors that underscores the infectious vulnerability of this patient population.

This case describes a TAFRO-like syndrome as a potential novel delayed immune-mediated phenomenon observed in the context of long-term CAR T-cell persistence after axi-cel therapy. As CAR T-cell therapies expand and long-term survivor numbers increase, recognition of delayed immune-mediated toxicities will become increasingly important.

Authors

Pedro José Mirete,[1] Mireia Micó-Cerdá,[1] Rafael Hernani,[1] Yassin El Bouzaydy,[2] Claudia Gómez-Hernández,[1] Soraya Ramos-Palao,[1] Laura Ventura-López,[1] Alicia Serrano-Alcalá,[1] Blanca Ferrer-Lores,[1] Ariadna Pérez-Martínez,[1] María Luisa Calabuig,[1] Mar Tormo,[1,3] María José Terol,[1,3] Jose Luis Piñana,[1] Carlos Solano[1,3] and Juan Carlos Hernández-Boluda[1,3]

[1]Hematology Department, Hospital Clínico Universitario de Valencia, INCLIVA Research Institute; [2]Department of Pathology, Hospital Clínico Universitario de Valencia and [3]Department of Medicine, University of Valencia, Valencia, Spain

Correspondence:
J.C. HERNÁNDEZ-BOLUDA - hernandez_jca@gva.es

https://doi.org/10.3324/haematol.2026.301307

Received: May 27, 2026.
Accepted: July 13, 2026.
Early view: July 23, 2026.

©2026 Ferrata Storti Foundation
Published under a CC BY-NC license

Disclosures

No conflicts of interest to disclose.

Contributions

PJM designed the report, collected and interpreted the clinical and molecular data, and wrote the manuscript. YEB performed and interpreted the histopathological studies. JCH-B, RH, CG-H, SR-P, LV-L, AS-A, BF-L, AP-M, MLC, MT, MJT, JLP, and CS contributed to patient management and data acquisition. All authors critically revised the manuscript for important intellectual content and approved the final version to be published.

Data-sharing statement

The data that support the findings of this study are available from the corresponding author upon reasonable request.

References

1. Rejeski K, Subklewe M, Aljurf M, et al. Immune effector cell–associated hematotoxicity: EHA/EBMT consensus grading and best practice recommendations. Blood. 2023;142(10):865-877.
2. Takai K, Nikkuni K, Shibuya H, Hashidate H. Thrombocytopenia with mild bone marrow fibrosis accompanied by fever, pleural effusion, ascites and hepatosplenomegaly. Rinsho Ketsueki. 2010;51(5):320-325.
3. Caballero JC, Conejero N, Solan L, Diaz de la Pinta FJ, Cordoba R, Lopez-Garcia A. Unraveling TAFRO syndrome: an in-depth look at the pathophysiology, management, and future perspectives. Biomedicines. 2024;12(5):1076.
4. Masaki Y, Kawabata H, Takai K, et al. 2019 Updated diagnostic criteria and disease severity classification for TAFRO syndrome. Int J Hematol. 2020;111(1):155-158.
5. Carubbi F, Alunno A, Matone E, Lucchesi A, Musuraca G, Ferri C. Intersecting paths between autoimmunity and bone marrow fibrosis: the case of autoimmune myelofibrosis. Autoimmun Rev. 2025;24(11):103893.
6. Henter JI, Horne A, Aricó M, et al. HLH-2004: Diagnostic and therapeutic guidelines for hemophagocytic lymphohistiocytosis. Pediatr Blood Cancer. 2007;48(2):124-131.
7. Wang H, Divaris K, Pan B, et al. Clonal hematopoiesis driven by mutated DNMT3A promotes inflammatory bone loss. Cell. 2024;187(14):3690-3711.
8. Zioni N, Bercovich AA, Chapal-Ilani N, et al. Inflammatory signals from fatty bone marrow support DNMT3A driven clonal hematopoiesis. Nat Commun. 2023;14(1):2070.
9. Avigan ZM, Catlett J, Bodnar S, et al. Clonal hematopoiesis and inflammation predict hematologic toxicity and secondary myeloid malignancies after B-cell maturation antigen-directed CAR-T cell therapy. Clin Cancer Res. 2025;31(20):4333-4344.
10. Sillito F, Rampotas A, Cheok K, et al. Clonal evolution and the risk of secondary myeloid neoplasia following chimeric antigen receptor T-cell therapy. Haematologica. 2025;110(11):2812-2818.
11. Yeung CCS, Voutsinas JM, Hirayama AV, et al. Abnormal bone marrow findings in patients following treatment with chimeric antigen receptor-T cell therapy. Eur J Haematol. 2024;112(1):111-121.
12. Morino J, Hirai K, Yoshida K, et al. Successful treatment of TAFRO syndrome with triple combination therapy of corticosteroid, tocilizumab, and cyclosporine. Cureus. 2025;17(3):e80274.
13. Locke FL, Neelapu SS, Bartlett NL, et al. Tocilizumab prophylaxis following axicabtagene ciloleucel in relapsed or refractory large B-cell lymphoma. Transplant Cell Ther. 2024;30(11):1065-1079.
14. Pan J, Deng B, Ling Z, et al. Ruxolitinib mitigates steroid-refractory CRS during CAR-T therapy. J Cell Mol Med. 2021;25(2):1089-1099.
15. Beckman JD, DaSilva A, Aronovich E, et al. JAK-STAT inhibition reduces endothelial prothrombotic activation and leukocyte-endothelial proadhesive interactions. J Thromb Haemost. 2023;21(5):1366-1380.